



## Pearls

# Fungal Nail Infections (Onychomycosis): A Never-Ending Story?

Mahmoud Ghannoum\*, Nancy Isham

Center for Medical Mycology, University Hospitals of Cleveland, Cleveland, Ohio, United States of America

## Is Onychomycosis Still a Problem?

The great majority of superficial fungal infections are caused by dermatophytes, which belong to one of three genera (*Trichophyton*, *Epidermophyton*, and *Microsporum*), with *T. rubrum* being the most prominent cause of nail infection (Figure 1). Table 1 summarizes the prevalence of various superficial fungal infections in different geographic areas [1]. Among superficial fungal infections, by far the most difficult to cure is toenail onychomycosis (Figure 2). The prevalence of onychomycosis has been reported to be as high as 23% across Europe [2] and 20% in East Asia [3]. In North America, the incidence of onychomycosis is up to 14% [4], with fungal infection responsible for 50% of all nail disease [5]. With millions of dollars being spent annually on oral and topical prescriptions, laser treatments, over-the-counter products, and home remedies, it is obvious that people are still bothered by their fungal toenail infections and are determined to get rid of them. Unfortunately, this is easier said than done. To successfully cure toenail onychomycosis requires long treatment duration that may extend to a full year. Even then, complete cure, defined as clinical cure (implying nail clearing) plus mycological cure (both negative microscopy and dermatophyte culture), is often unattainable.

## What Are the Risk Factors for Toenail Onychomycosis?

The most prevalent predisposing risk factor for developing onychomycosis is advanced age, which is reported to be 18.2% in patients 60–79 years of age, compared to 0.7% in patients younger than 19 years of age. Further, men are up to three times more likely to have onychomycosis than women, though the reasons for this gender difference are not clear [6]. Moreover, the low prevalence of infection in people whose spouses have onychomycosis compared to the prevalence among their children suggests a genetic risk factor [7]. Though extremely rare, one study reported four family members from seven unrelated groups with a common genetic trait (autosomal recessive CARD9 deficiency) who developed a dermatophyte infection of deep tissues that proved fatal [8].

Other risk factors include diabetes and conditions contributing to poor peripheral circulation [9]. In fact, onychomycosis may represent an important predictor for the development of diabetic foot syndrome and foot ulcers [10]. Patients who are immunosuppressed, such as those with HIV infection and those undergoing cancer therapy, are also predisposed to fungal nail infection [11]. There is at least one case report of a toenail infection caused by *Fusarium* (a non-dermatophyte fungus) that developed into a fatal systemic infection in a lymphoma patient following a bone marrow transplant [12].

Several nonclinical risk factors also affect a person's chance of developing fungal nail infections. Toenail onychomycosis is not prevalent in tropical climates, presumably because people in those areas are not in the habit of wearing occlusive footwear that create a warm, moist environment for the proliferation of fungi. Further,

the spread of foot infections, including tinea pedis (athlete's foot), may occur in places such as shower stalls, bathrooms, or locker rooms where floor surfaces often are wet and people are barefoot [13]. Nail trauma will also increase the risk of fungal infection of the affected nail, especially in the geriatric population [11].

A recent study by our group utilized regression analysis to show that history of tinea pedis plus three clinical variables—onychomycosis, plantar scaling (a clinical sign of tinea pedis), and nail discoloration (a clinical sign of onychomycosis and generally indicative of severe nail infection) were statistically associated with spread of infection in households with multiple infected members ( $P \leq .044$ ) [14].

## How Is Onychomycosis Treated?

Treatment of onychomycosis includes chemical or surgical removal of the infected nail, systemic or topical drugs, pulse therapy, or a combination thereof. Table 2 is a summary of oral and topical therapy regimens; as can be seen, the course of treatment for fingernail infections is shorter than for toenail infections. The treatment of onychomycosis has improved considerably over the past several decades, following the introduction of the oral antifungals terbinafine and itraconazole. However, these drugs may have side effects such as liver damage or drug interactions, which are particularly relevant in the elderly population [15]. Further, nail infections caused by non-dermatophyte organisms, such as *Fusarium*, are especially difficult to treat [16].

## Why Don't Topical Antifungals Work Better?

Unfortunately, currently available topical agents, such as amorolfine 5% and ciclopirox 8%, have low efficacy (approximately 5%–12%) [17,18]. This low efficacy can mainly be attributed to the inability of the drug to penetrate through the nail plate to the nail bed where the infection resides [19]. Thickened nails, extensive involvement of the entire nail, lateral disease, and yellow spikes contribute to a poor response to topical

**Citation:** Ghannoum M, Isham N (2014) Fungal Nail Infections (Onychomycosis): A Never-Ending Story? PLoS Pathog 10(6): e1004105. doi:10.1371/journal.ppat.1004105

**Editor:** William E. Goldman, The University of North Carolina at Chapel Hill, United States of America

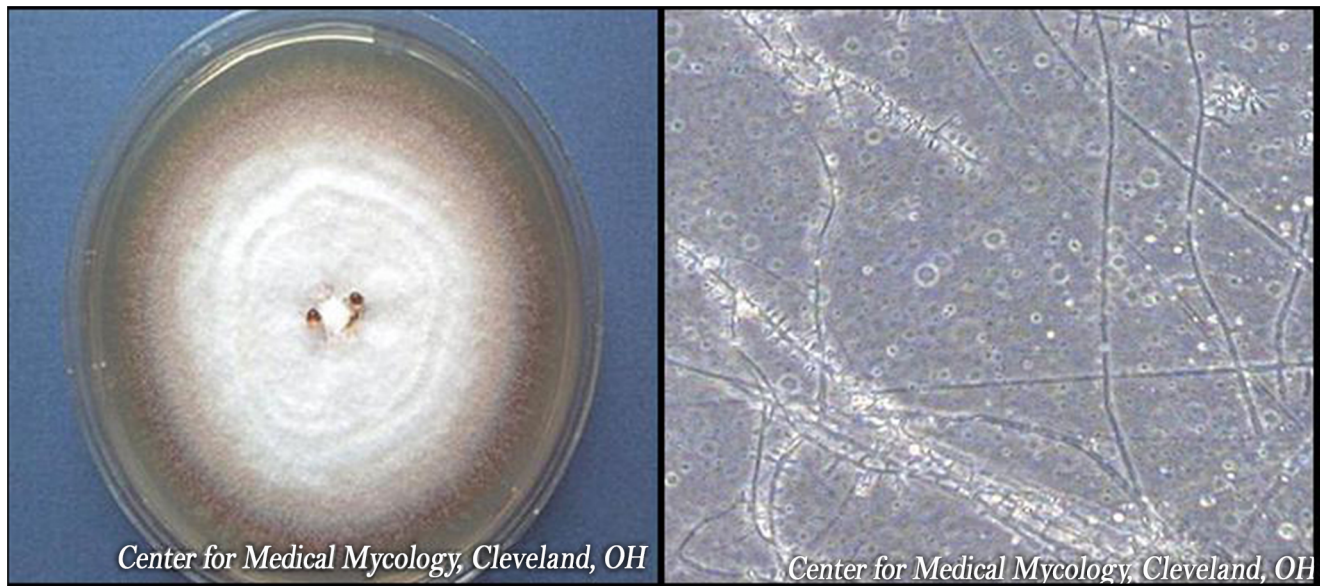
**Published:** June 5, 2014

**Copyright:** © 2014 Ghannoum, Isham. This is an open-access article distributed under the terms of the Creative Commons Attribution License, which permits unrestricted use, distribution, and reproduction in any medium, provided the original author and source are credited.

**Funding:** The authors have received no specific funding for this work.

**Competing Interests:** The authors have declared that no competing interests exist.

\* E-mail: mahmoud.ghannoum@case.edu



**Figure 1. *Trichophyton rubrum* colony and microscopic appearance (40x).**  
doi:10.1371/journal.ppat.1004105.g001

treatment [11]. Figure 1 shows an example of distal subungual onychomycosis, trimmed to demonstrate nail thickening.

Further complicating the scenario is the fact that certain antifungals will bind to the nail plate and thus may not be available at the site of infection, which is the nail bed. For example, terbinafine has been shown to accumulate rapidly in the nail, reaching a maximum of 0.39 mg/g and persisting up to 2 months following the end of treatment [20]. In this regard, Ryder et al. developed an in vitro nail model that showed that the cidal action of terbinafine, when tested against an established dermatophyte infection in the presence of human nail, was in fact less effective than in conventional microdilution assays where no nail powder is present [21].

Many different approaches to solving the problem of nail penetration have been attempted recently. For example, there have been attempts to develop penetration enhancers to facilitate drug delivery through the nail plate, such as addition of dodecyl-2-N,N-dimethylaminopropionate hydrochloride (DDAIP HCl, trade name NexACT-88; NexMed) to terbina-

fine nail lacquer [19]. Another technique to enhance the penetration of nail lacquer was the incorporation of terbinafine into transfersome lipid vesicles, which are highly deformable and thus are able to pass through intercellular spaces [22]. Additionally, a novel small-molecule oxaborole antifungal (AN2690) has recently been developed that is designed for greater penetration through the nail plate [23]. However, to date, none of these topical products has been commercialized.

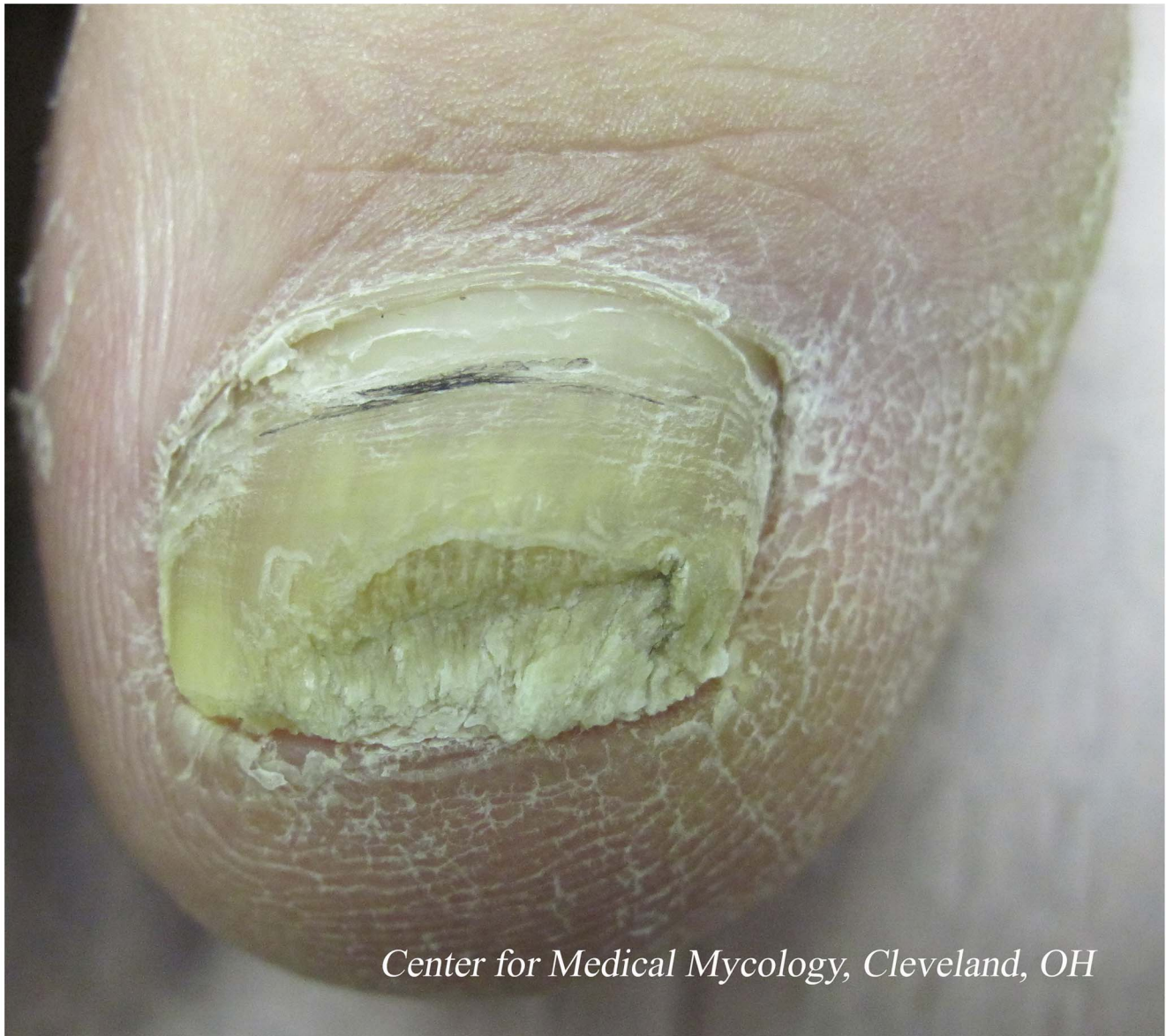In this regard, approval of topical onychomycosis drugs by regulatory agencies may be negatively impacted by an overly stringent definition of complete cure, which includes nail clearing plus mycological cure (negative microscopy and culture). Review of data from several international clinical trials by Ghannoum et al. has suggested that reassessment of the definition of onychomycosis cure is critical [24]. In these trials, a high number of toenail samples collected from subjects at the end of clinical trials contained visible fungal hyphae that subsequently failed to grow upon culture. However, current

**Table 1. Most prevalent dermatophytosis in different regions worldwide.**

| Region                       | Dermatophytosis               | Causative Organism                          |
|------------------------------|-------------------------------|---|
| North/South America          | Tinea pedis, onychomycosis    | <i>T. rubrum</i>                            |
| Western Europe               | Tinea pedis, onychomycosis    | <i>T. rubrum</i>                            |
| Russia                       | Onychomycosis                 | <i>T. rubrum</i>                            |
| Mediterranean (Italy/Greece) | Tinea corporis, tinea capitis | <i>M. canis</i>                             |
| Turkey                       | Tinea pedis                   | <i>T. rubrum</i>                            |
| North Africa/tropical Africa | Tinea corporis                | <i>T. violaceum</i> , <i>M. audouinii</i>   |
| China/Japan                  | Tinea pedis, onychomycosis    | <i>T. rubrum</i>                            |
| India                        | Tinea corporis                | <i>T. rubrum</i>                            |
| Asia                         | Tinea pedis, onychomycosis    | <i>T. rubrum</i> , <i>T. mentagrophytes</i> |
| Australia                    | Tinea pedis, onychomycosis    | <i>T. rubrum</i> , <i>T. mentagrophytes</i> |

\*Data for this table was compiled from Havlickova et al. [1].  
doi:10.1371/journal.ppat.1004105.t001





**Figure 2. Distal subungual onychomycosis of the great toenail.**  
doi:10.1371/journal.ppat.1004105.g002

technology does not differentiate between “live” and “dead” fungi, so even though these samples had to be reported as microscopy-positive, the infection may in fact have been cured. The authors propose that, for clinical trials of topical agents, the length of treatment should be extended to 18 months, followed by a longer washout period of 3–6 months before primary assessments to allow the removal of both residual drug in the nail and nonviable fungal cells. Therefore, the absence of clinical signs following an adequate wash out period, coupled with a negative culture, with or without negative microscopy, should be considered the definition of onychomycosis cure. These changes may enable more topical agents to be proven efficacious.

### **What’s New in Onychomycosis Therapy?**

Recent device-based therapies for onychomycosis include laser devices, photodynamic therapy, iontophoresis, and

ultrasound. Laser treatment has been approved for cosmetic treatment only, but efficacy as a treatment to eradicate the fungal infection will have to be determined by additional randomized controlled trials [25]. There have been rare reports of onychomycosis cures following the use of phototherapy, which involves the irradiation of accumulated protoporphyrin within the fungal hyphae, leading to subsequent hyphal cell damage [26]. The ability of iontophoresis, or the use of electric current ( $0.5 \text{ mA/cm}^2$ ) to facilitate the passage of drug through the nail plate, has been proven in studies with human cadaver nails, but relevant clinical studies remain to be conducted [27]. Finally, though ultrasound therapy has preliminarily demonstrated fungistatic activity against nail infections [28], the device itself seems overly complicated, with ultrasound transducers and drug delivery compartments needed above each toenail and the requirement for a computer software interface, making it a physician-office-only treatment and likely very expensive [29].

**Table 2.** Treatment of onychomycosis with antifungal agents.

| Agent                   | Dose                       | Duration  |
|-------------------------|----------------------------|---|
| Terbinafine             | 250 mg                     | Toenails: once per day for 12 weeks   |
|                         |                            | Fingernails: once per day for 6 weeks   |
| Itraconazole            | 200 mg                     | Toenails: once per day for 12 weeks   |
|                         | pulse therapy              | Toenails: 200 mg twice per day for 1 week/no treatment for 3 weeks. Repeat for 3–4 months<br>Fingernails: 200 mg twice per day for 1 week/no treatment for 3 weeks. Repeat for 2 months |
| Fluconazole             | 300–450 mg                 | Toenails: once/week for 9–12 months   |
|                         | 150–300 mg                 | Fingernails: once/week for 4–6 months   |
| Ciclopirox nail lacquer | apply once per day         | Remove lacquer once per week. Treat for up to 48 weeks  |
| Amorolfine nail lacquer | apply once or twice a week | Remove lacquer before each new application. Toenails: 9–12 months. Fingernails: 6 months  |

doi:10.1371/journal.ppat.1004105.t002

### Why Do Patients So Often Relapse?

There are multiple factors that may contribute to the high rate of fungal nail infection recurrence. Patients with a genetic predisposition to onychomycosis, who are immunocompromised, or who have diabetes, are likely to experience relapse and may never achieve a permanent cure [11].

This may be due either to failure to eradicate the infecting fungus or to re-infection with a new fungal strain following subsequent exposure. Arthroconidia, which are chains of fungal conidia that are formed by breakage of the fungal hyphae, are considered to be the primary means of nail invasion. These arthroconidia, which have thicker cell walls than conidia formed *in vitro*, have been shown to be more resistant to antifungals and, thus, may remain in the nail bed as a reservoir for recurrent disease [30]. However, the incidence of innate resistance among dermatophytes is low. Our Center conducted *in vitro* susceptibility testing of 140 sequential isolates from subjects who failed treatment in an oral terbinafine clinical trial. In all cases, the minimum inhibitory concentrations (MICs) of terbinafine against each patient set were identical or within one tube dilution, implying no resistance development. The same results were obtained within each set with fluconazole, itraconazole, and

griseofulvin (with the exception of one isolate having a 3-fold increase in the MIC). This further indicates that there was no crossresistance between antifungal agents [31]. This study showed that failure to cure the infected nails may be due to host/family factors.

Even in cases where the infecting fungus has been entirely eradicated by antifungal therapy, patients remain at risk for re-infection. As mentioned above, people are exposed to dermatophyte reservoirs in many of their day-to-day activities, including trips to the gym and increased travel. Common sense measures, such as not walking barefoot through public showers or hotel rooms, would help prevent unnecessary exposure. That being said, one of the most common routes of infection is within households. It has long been suspected that nail infections were spread by close contact with family members. However, it wasn't until recently that our group was able to employ molecular techniques to prove that persons within the same household were infected by the same strain of *T. rubrum* [14]. For those attempting to avoid re-infection, measures such as spraying their shoes with a topical antifungal spray or treating them with a commercial ultraviolet device [32] after each wearing would be prudent. Thus, a patient not only needs to treat the infection but also break the cycle of re-infection.

### References

- Havlickova A, Czaika VA, Friedrich M (2008) Epidemiological trends in skin mycoses worldwide. *Mycoses* 51 S4: 2–15.
- Haneke E, Roseeuw D (1999) The scope of onychomycosis: epidemiology and clinical features. *Int J Dermatol* 38 Suppl 2: 7–12.
- Ogasawara Y (2003) Prevalence and patient's consciousness of tinea pedis and onychomycosis. *Nihon Ishinkin Gakkai Zasshi* 44: 253–260.
- Ghannoum MA, Hajjeh RA, Scher R, Konnikov N, Gupta AK, et al. (2000) A large-scale North American study of fungal isolates from nails: the frequency of onychomycosis, fungal distribution, and antifungal susceptibility patterns. *J Am Acad Dermatol* 43: 641–648.
- Scher RK (1994) Onychomycosis is more than a cosmetic problem. *Br J Dermatol* 130: 15.
- Gupta AK, Jain HC, Lynde CW, MacDonald P, Cooper EA, et al. (2000) Prevalence and epidemiology of onychomycosis in patients visiting physicians' offices: a multicenter Canadian survey of 15,000 patients. *J Am Acad Dermatol* 43: 244–248.
- Faergemann J, Correia O, Nowicki R, Ro BI (2005) Genetic predisposition - understanding underlying mechanisms of onychomycosis. *J Eur Acad Dermatol Venerol* 19: 17–19.
- Lantermier F, Pathan S, Vincent QB, Liu L, Cypowyj S, et al. (2013) Deep dermatophytosis and inherited CARD9 deficiency. *N Engl J Med* 369: 1704–1714.
- Saunte DM, Holgersen JB, Haedersdal M, Strauss G, Bitsch M, et al. (2006) Prevalence of toe nail onychomycosis in diabetic patients. *Acta Derm Venerol* 86: 425–428.
- Nenoff P, Ginter-Hanselmayer G, Tietz HJ (2012) Fungal nail infections - an update: Part 1 - Prevalence, epidemiology, predisposing conditions, and differential diagnosis. *Hautarzt* 63: 30–38.
- Scher RK, Baran R (2003) Onychomycosis in clinical practice: factors contributing to recurrence. *Br J Dermatol* 149: 5–9.
- Arrese JE, Pierard-Franchimont C, Pierard GE (1996) Fatal hyalohyphomycosis following *Fusarium* onychomycosis in an immunocompromised patient. *Am J Dermatopathol* 18: 196–198.
- Aly R (1994) Ecology and epidemiology of dermatophyte infections. *J Am Acad Dermatol* 31: S21.
- Ghannoum MA, Mukherjee PK, Warshaw EM, Evans S, Korman NJ, et al. (2013) Molecular analysis of dermatophytes suggest spread of infection among household members. *Cutis* 91: 237–246.
- Elewski B, Tavakkol A (2005) Safety and tolerability of oral antifungal agents in the treatment of fungal nail disease: a proven reality. *Ther Clin Risk Manag* 1: 299–306.
- Tosti A, Piraccini BM, Lorenzi S (2000) Onychomycosis caused by nondermatophyte molds: clinical features and response to treatment of 59 cases. *J Am Acad Dermatol* 42: 217–224.
- BlueCross BlueShield of Northeastern New York (2006 November 28) Drug Therapy Guidelines: Antifungal Agents Lamisil (terbinafine), Sporanox (itraconazole), Penlac (ciclopirox), Vfend (voriconazole). Drug P&T Newsletter.
- Lauharanta J (1992) Comparative efficacy and safety of amorolfine nail lacquer 2% versus 5% once weekly. *Clin Exp Dermatol* 17: 41–43.

19. Ghannoum MA, Long L, Pfister WR (2009) Determination of the efficacy of terbinafine hydrochloride nail solution in the topical treatment of dermatophytosis in a guinea pig model. *Mycoses* 52: 35–43.
20. Faergemann J, Zehender H, Millerioux L (1994) Levels of terbinafine in plasma, stratum corneum, dermis-epidermis (without stratum corneum), sebum, hair and nails and after 250 mg terbinafine orally once daily for 7 and 14 days. *Clin Exp Dermatol* 19: 121–126.
21. Osborne CS, Leitner I, Favre B, Ryder NS (2004) Antifungal drug response in an in vitro model of dermatophyte nail infection. *Med Mycol* 42: 159–163.
22. Ghannoum M, Isham N, Herbert J, Henry W, Yurdakul S (2011) Activity of TDT 067 (Terbinafine in Transfersome) against Agents of Onychomycosis, as Determined by Minimum Inhibitory and Fungicidal Concentrations. *J Clin Microbiol* 49: 1716–1720.
23. Alley MR, Baker SJ, Beutner KR, Plattner J (2007) Recent progress on the topical therapy of onychomycosis. *Expert Opin Investig Drugs* 16: 157–167.
24. Ghannoum M, Isham N, Catalano V (2013) A Second Look at Efficacy Criteria for Onychomycosis: Clinical and Mycological Cure. *Br J Dermatol*. E-pub ahead of print. doi:10.1111/bjd.12594.
25. Gupta AK, Simpson FC (2013) Laser therapy for onychomycosis. *J Cutan Med Surg* 17: 301–307.
26. Harris F, Pierpoint L (2012) Photodynamic therapy based on 5-aminolevulinic acid and its use as an antimicrobial agent. *Med Res Rev* 32: 1292–1327.
27. Delgado-Charro MB (2012) Iontophoretic drug delivery across the nail. *Expert Opin Drug Deliv* 9: 91–103.
28. Silva JL, Doimo G, Faria DP (2011) The use of high frequency waves to treat onychomycosis: preliminary communication of three cases. *An Bras Dermatol* 86: 598–600.
29. Abadi D, Zderic V (2011) Ultrasound-mediated nail drug delivery system. *J Ultrasound Med* 30: 1723–1730.
30. Yazdanparast SA, Barton RC (2006) Arthroconidia production in *Trichophyton rubrum* and a new ex vivo model of onychomycosis. *J Med Microbiol* 55: 1577–1581.
31. Bradley M, Leidich S, Isham N, Elewski B, Ghannoum M (1999) Antifungal susceptibilities and genetic relatedness of serial *Trichophyton rubrum* isolates from patients with onychomycosis of the toenail. *Mycoses* 42: 105–110.
32. Ghannoum MA, Isham N, Long L (2012) Optimization of an infected shoe model for the evaluation of an ultraviolet shoe sanitizer device. *J Am Podiatr Med Assoc* 102: 309–313.