

RESEARCH ARTICLE

Mercury in the retina and optic nerve following prenatal exposure to mercury vapor

Roger Pamphlett^{1,2*}, Stephen Kum Jew¹, Svetlana Cherepanoff^{3,4,5}

1 Discipline of Pathology, Sydney Medical School, Brain and Mind Centre, The University of Sydney, Sydney, Australia, **2** Department of Neuropathology, Royal Prince Alfred Hospital, Sydney, Australia, **3** Sydpath, St Vincent's Hospital, Sydney, Australia, **4** Northern Clinical School, The University of Sydney, Sydney, Australia, **5** St Vincent's Clinical School, University of New South Wales, Sydney, Australia

* roger.pamphlett@sydney.edu.au

Abstract

Damage to the retina and optic nerve is found in some neurodegenerative disorders, but it is unclear whether the optic pathway and central nervous system (CNS) are affected by the same injurious agent, or whether optic pathway damage is due to retrograde degeneration following the CNS damage. Finding an environmental agent that could be responsible for the optic pathway damage would support the hypothesis that this environmental toxicant also triggers the CNS lesions. Toxic metals have been implicated in neurodegenerative disorders, and mercury has been found in the retina and optic nerve of experimentally-exposed animals. Therefore, to see if mercury exposure in the prenatal period could be one link between optic pathway damage and human CNS disorders of later life, we examined the retina and optic nerve of neonatal mice that had been exposed prenatally to mercury vapor, using a technique, autometallography, that detects the presence of mercury within cells. Pregnant mice were exposed to a non-toxic dose of mercury vapor for four hours a day for five days in late gestation, when the mouse placenta most closely resembles the human placenta. The neonatal offspring were sacrificed one day after birth and gapless serial sections of formalin-fixed paraffin-embedded blocks containing the eyes were stained with silver nitrate autometallography to detect inorganic mercury. Mercury was seen in the nuclear membranes of retinal ganglion cells and endothelial cells. A smaller amount of mercury was present in the retinal inner plexiform and inner nuclear layers. Mercury was conspicuous in the peripapillary retinal pigment epithelium. In the optic nerve, mercury was seen in the nuclear membranes and processes of glia and in endothelial cells. Optic pathway and CNS endothelial cells contained mercury. In conclusion, mercury is taken up preferentially by fetal retinal ganglion cells, optic nerve glial cells, the retinal pigment epithelium, and endothelial cells. Mercury induces free radical formation, autoimmunity, and genetic and epigenetic changes, so these findings raise the possibility that mercury plays a part in the pathogenesis of degenerative CNS disorders that also affect the retina and optic nerve.



OPEN ACCESS

Citation: Pamphlett R, Kum Jew S, Cherepanoff S (2019) Mercury in the retina and optic nerve following prenatal exposure to mercury vapor. PLoS ONE 14(8): e0220859. <https://doi.org/10.1371/journal.pone.0220859>

Editor: Jyotshna Kanungo, National Center for Toxicological Research, UNITED STATES

Received: February 18, 2019

Accepted: July 24, 2019

Published: August 7, 2019

Copyright: © 2019 Pamphlett et al. This is an open access article distributed under the terms of the [Creative Commons Attribution License](https://creativecommons.org/licenses/by/4.0/), which permits unrestricted use, distribution, and reproduction in any medium, provided the original author and source are credited.

Data Availability Statement: All relevant data are within the paper.

Funding: The authors received no specific funding for this work.

Competing interests: The authors have declared that no competing interests exist.

Introduction

The optic pathway is a frequent site of pathology in human central nervous system (CNS) diseases, with retinal atrophy being described in people with Alzheimer disease, Parkinson disease and amyotrophic lateral sclerosis [1]. Optic neuritis is a common early manifestation in multiple sclerosis, and retinal atrophy occurs in multiple sclerosis without the presence of optic neuritis [2]. In all these disorders, thinning of the inner retina appears to be the most prominent feature, usually because of atrophy of the nerve fibre layer [1]. The retina and optic nerve are extensions of the central nervous system, so optic pathway changes may be secondary to CNS damage. On the other hand, the initiating pathogenetic agent that triggers the disorder in the brain could also involve the optic pathway, since eye signs are present before damage to the brain becomes apparent [1]. There is increasing interest in the concept the early life exposures to toxicants influence the onset of later life disorders [3], probably through epigenetic mechanisms [4]. A study of the retina and optic nerve in fetal mice that have been exposed to toxic environmental agents could therefore give clues to the underlying pathogenesis of these disorders.

Toxic metals such as mercury have been implicated in neurological disorders, and could act in combination with genetic or other susceptibilities to cause widespread cell damage [5,6]. In addition, mercury has been thought to be responsible for several human retinal disorders [7,8,9]. Mercury has been located in the adult primate retina and optic nerve after exposure to mercury vapor [10]. This led us to wonder if mercury localises to the same regions in the fetus, where it might lead to genetic or epigenetic changes that predispose to later-life disorders [11]. Mercury vapor crosses the rodent placenta readily, and rodents in late gestation develop a chorioallantoic placenta like that of humans [12]. Furthermore, human exposure to mercury during pregnancy is common, mostly from fish consumption or from mercury-containing amalgam dental restorations, and mercury in human maternal blood crosses the placenta to enter the fetal circulation [13]. We therefore exposed mice in late pregnancy to non-toxic levels of mercury vapor and used a histochemical method, autometallography, to look for the presence of mercury in the eyes, optic nerves and brains of their neonatal offspring.

Materials and methods

Study design

Tissue blocks from a project that studied the effect of transplacental mercury on the developing brain and spinal cord [12] were sectioned to examine the eyes and optic nerves. Briefly, over gestational days 14–18, four C57 pregnant mice were exposed to a non-toxic dose of 0.5 mg/m³ of mercury vapor for 4 hours a day. One pup from each litter was sacrificed with carbon dioxide on postnatal day 1 and fixed in 10% formalin. Serial 3 mm blocks of tissue were taken throughout the head and body and processed routinely for embedding in paraffin wax. Control pups with no fetal mercury exposure were sacrificed at the same time and treated in the same manner. In paraffin blocks containing the eyes, a 7 µm section was first cut and stained with hematoxylin, followed by 7 µm gapless serial sections throughout the whole block, all stained with silver nitrate autometallography (AMG) to detect inorganic mercury attached to sulphides or selenides, which is visible microscopically as black silver-coated mercury grains [14]. In each staining run, a mouse spinal cord section where motor neuron cell bodies were known to contain mercury after an intraperitoneal injection of mercuric chloride [15] was included as a positive control.

Ethics

The methods to expose mice to mercury vapor, animal housing, handling, sacrifice, and tissue preparation had been approved by the University of Sydney Animal Ethics Committee [12].

Because this work was undertaken on archived paraffin tissue blocks the ethics committee waived the requirement for renewal of the ethics protocol.

Results

Clinical

Dams, and other offspring exposed to the same dose of mercury vapor but not sacrificed, suffered no ill-effects, and fed, moved, behaved, and gained weight normally [12].

The neonatal mouse retina

The neonatal mouse eye is relatively underdeveloped (the eye only opens on postnatal day 9) so there are several anatomical differences between it and a human adult eye [16]. However, the origins of the adult retinal layers are seen in the neonate (Fig 1). The neonatal mouse has an incomplete inner blood-retinal barrier since transcytosis is only suppressed from postnatal day 10 onwards [17].

The anatomy of the neonatal mouse eye and optic nerve head is seen in Fig 2. At postnatal day 1 the immature mouse eye is still covered by skin. The ganglion cells are numerous but undeveloped. The inner neuroblast layer (the future inner nuclear layer) is a layer of slightly paler-staining cells adjacent to the outer neuroblastic layer, where the photoreceptors form (Figs 3 and 4B) [16].

Mercury in the neonatal mouse retina

Mercury staining was visible in the ganglion cell layer, where it was attached to the nuclear membranes of the ganglion cells and in endothelial cells (Fig 4A). Scattered mercury staining was present in the nerve fibre and inner plexiform layers, and in nuclear membranes and capillary walls of the inner nuclear layer. Mercury in the inner retina cells was most prominent at the posterior pole of the eye, with decreasing staining with increasing distance from the posterior pole, until no mercury was seen in cells at the anterior pole. No mercury was seen in the outer neuroblast (future photoreceptor) layer. No other areas of the eye, including the anterior segment, contained mercury. No black grains were seen in any eyes or optic nerves of mercury-exposed mice that were stained with hematoxylin only. No AMG grains were seen in the retina of mice that had not been exposed to prenatal mercury vapor (Fig 4B).

In neonatal mice exposed to prenatal mercury vapor, dense mercury staining was present in the peripapillary retinal pigment epithelium (Fig 5), with decreasing amounts of mercury in pigment epithelial cells further from the optic nerve head (Fig 6A). No mercury was seen in the anterior retinal pigment epithelium (inset in Fig 6A).

Mercury in the neonatal mouse optic nerve

Mercury staining was prominent in the optic nerve head, where it was present in glial cell nuclear membranes and processes, as well as in endothelial cells (Fig 6B). Mercury was seen in same cells in the intra-orbital and intracranial optic nerves (Fig 7A), as well as in endothelial cells of the pial vascular plexuses supplying the bodies of the optic nerves (Fig 7B).

Mercury in the neonatal brain endothelial cells and meninges

Mercury was seen in the brain leptomeninges (Fig 7A) and in scattered endothelial cells of capillaries within the brain parenchyma, where the mercury appeared to be attached to the nuclear membranes (Fig 8). No mercury was seen in the processes, perikarya or nuclear membranes of brain neurons or glial cells, as noted previously [12].

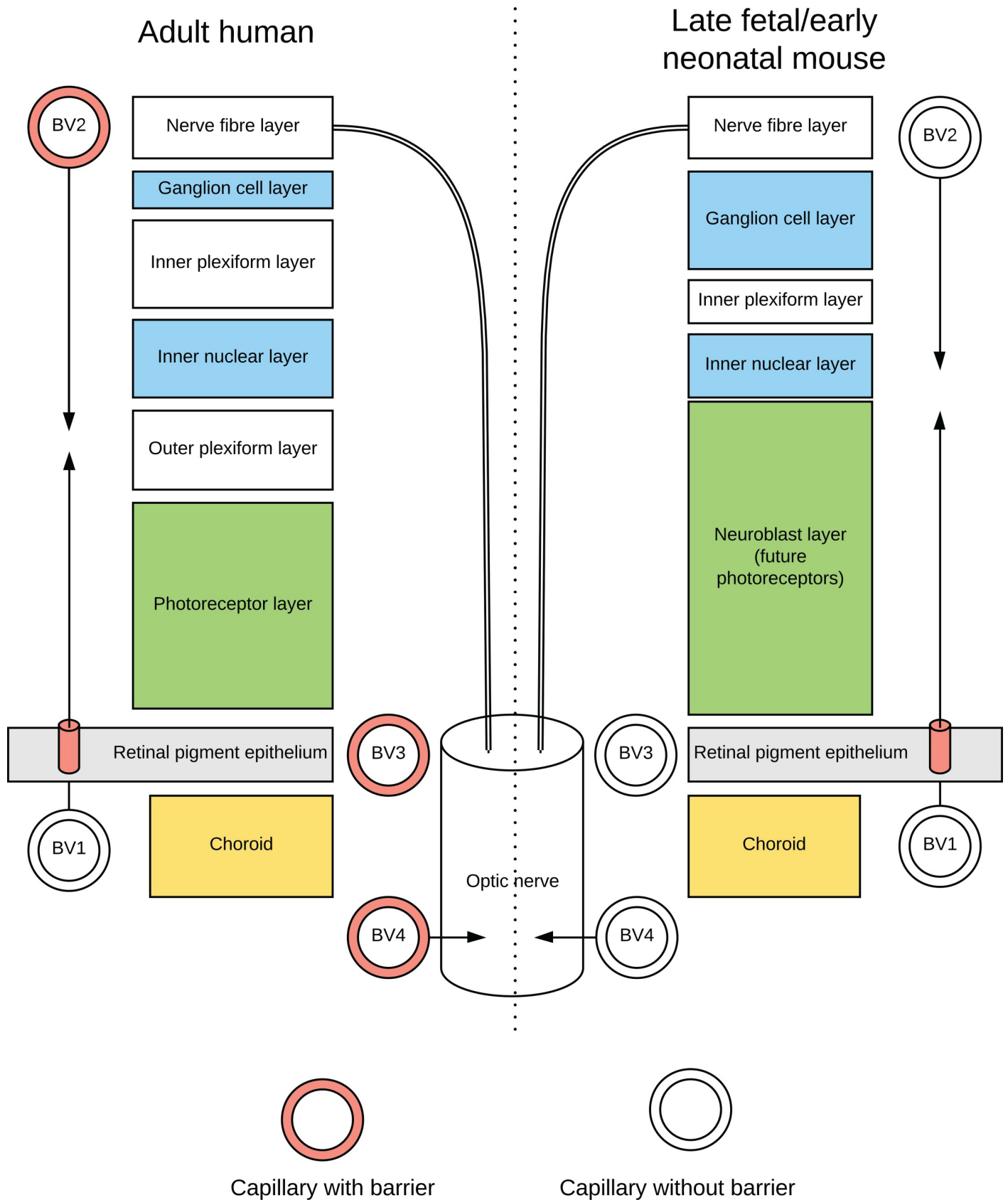


Fig 1. Diagram comparing eye anatomy of the adult human and neonatal mouse. The outer retinal layers are supplied by blood vessels (BV1) from the posterior ciliary arteries, terminating in the choriocapillaris, a fenestrated capillary network without tight junctions. An outer blood-retinal barrier is formed by tight junctions in the retinal pigment epithelial cells, after which oxygen is supplied by diffusion to the outer retina. An inner blood-retinal barrier is formed by adult capillary endothelial cells with tight junctions (BV2, filled walls) originating from the central retinal artery. The optic nerve head is supplied primarily by a vascular circle (BV3) from the posterior ciliary arteries, and from the peripapillary choroid vessels. The body of the optic nerve is supplied from the ophthalmic artery via the pial plexus of blood vessels which penetrate the nerve (BV4). The endothelial cells of adult optic nerve capillaries have tight junctions, forming a blood-optic nerve barrier. Capillaries of the inner retina, and possibly the optic nerve, have limited blood-retina and blood-optic nerve barriers (unfilled walls) in the late fetal mouse.

<https://doi.org/10.1371/journal.pone.0220859.g001>

Neonatal mice not exposed to mercury

In neonatal mice that had not been exposed to prenatal mercury vapor, no AMG staining was seen in the inner retina (Fig 4B), retinal pigment epithelium, optic nerves or endothelial cells.

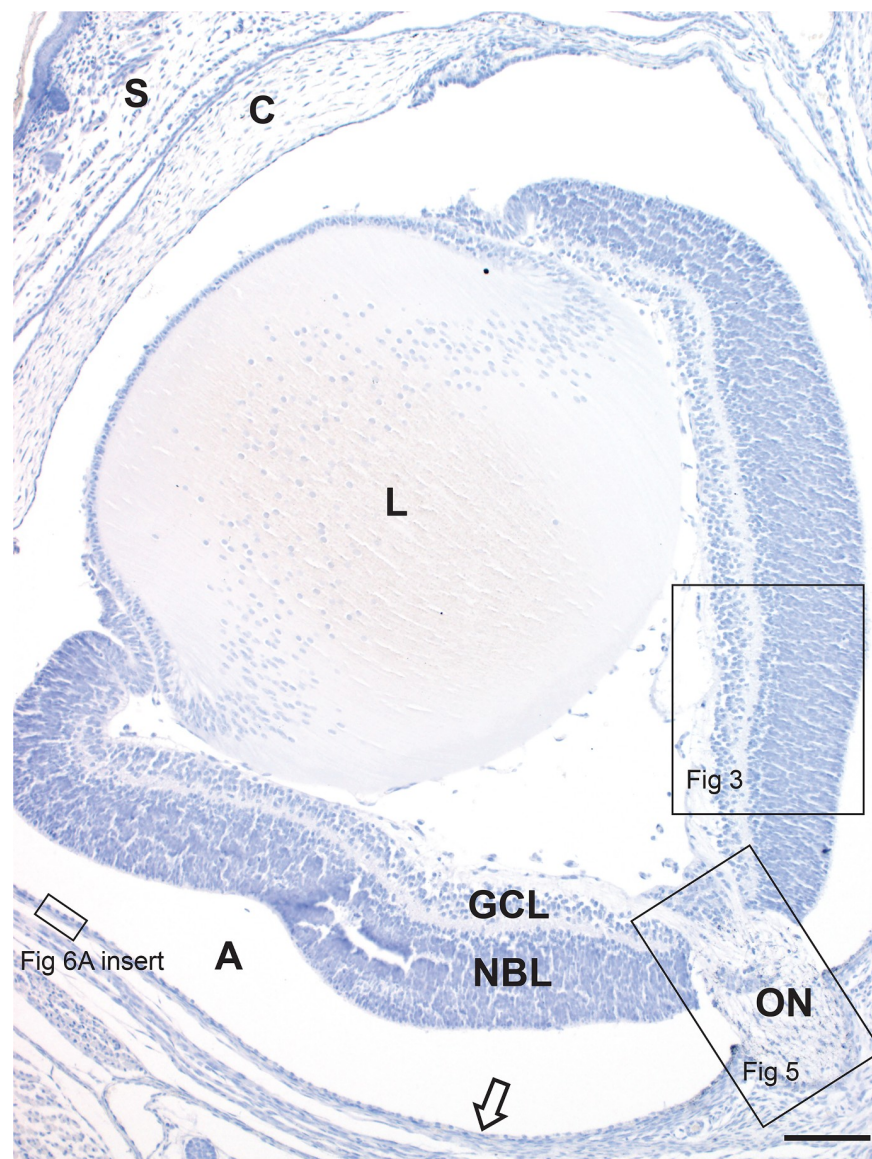


Fig 2. The neonatal mouse eye. Skin (S) covers the eye of the neonatal mouse. The ganglion cell layer (GCL) and neuroblast layer (NBL) of the retina are separated by a pale inner plexiform layer (for more detail see Fig 3). The optic nerve (ON) is seen at the lower right of the image (for more detail see Fig 5). The retinal pigment epithelium (arrow) is separated from the rest of the retina by an artefactual space (A). C: Cornea, L: lens. AMG/hematoxylin, Bar = 100 μ m.

<https://doi.org/10.1371/journal.pone.0220859.g002>

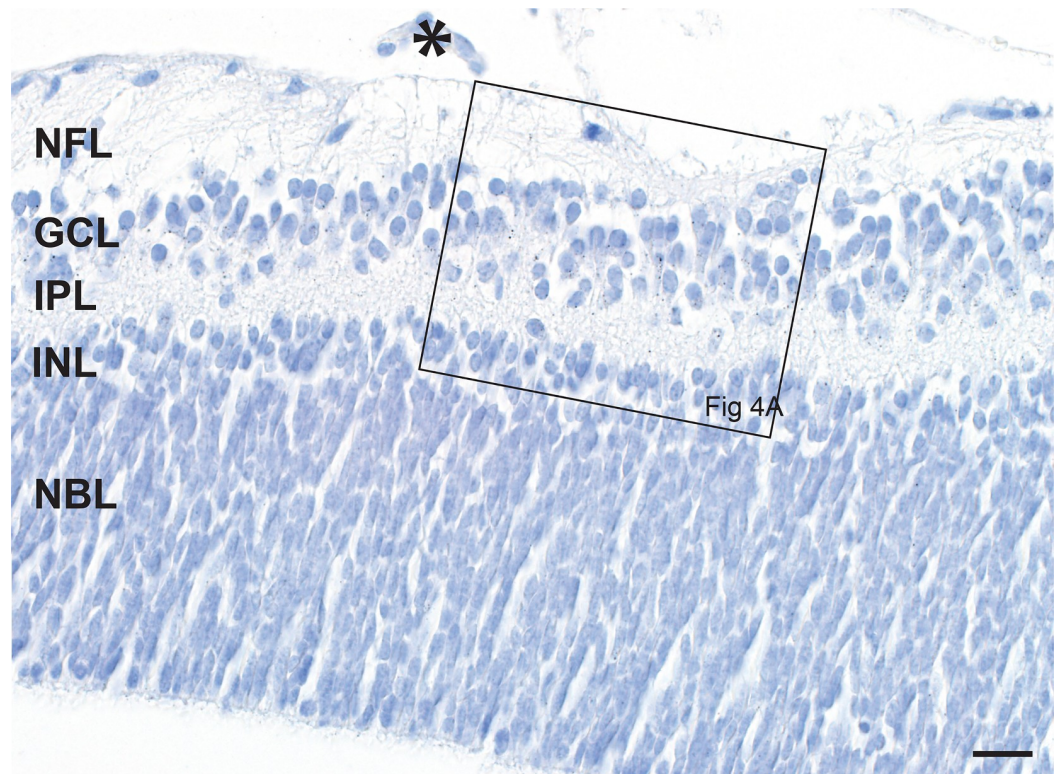


Fig 3. The neonatal mouse retina. Ganglion cells in the ganglion cell layer (GCL) are numerous in the neonatal mouse, and the nerve fibre layer (NFL) is prominent. Involuting hyaloid vessels (asterisk) are seen on the surface of the retina. The future inner nuclear layer (INL) is three-to-four cells thick below the inner plexiform layer (IPL), with slightly paler nuclei (best seen in Fig 4B) than the underlying neuroblast layer (NBL), the source of the photoreceptors. At this magnification black AMG grains are just visible in the ganglion cell layer (see Fig 4A for a high power view). AMG/hematoxylin, Bar = 20 μ m.

<https://doi.org/10.1371/journal.pone.0220859.g003>

Discussion

Key findings of this study were that after exposure to mercury vapor in late pregnancy, mercury was taken up preferentially in fetal retinal ganglion cells, the peripapillary retinal pigment epithelium, optic nerve glia and endothelial cells. Mercury appeared to have a predilection for the nuclear membrane of cells.

The distribution of mercury we found in the fetal retina and optic nerve is similar to that described in the adult squirrel monkey after exposure to mercury vapor, where autometallography was also used to demonstrate the presence of mercury within cells; mercury was still visible in these cells some years after exposure, indicating that these tissues retain mercury for long periods of time [10]. Mercury vapor also localises to the retina of the adult mouse eye [18], and to the retina of the adult rat and Marmoset monkey [19], while organic mercury localises to the optic nerve of larval zebrafish [20]. In these studies, however, the cellular distribution of the mercury could not be determined.

Unlike inorganic mercury, mercury vapor (with human exposure mostly from industrial occupations or mercury-containing dental amalgam restorations) and methylmercury (mostly from eating fish) both cross the placenta readily [21,22,23]. Methylmercury is slowly demethylated in fetal tissues into inorganic mercury [24]. Much of inhaled mercury vapor is oxidised in red blood cells to inorganic mercury by catalase, and inhibitors of catalase, such as ethanol, increase the amount of mercury vapor that is available to cross the placenta [25]. Mercury

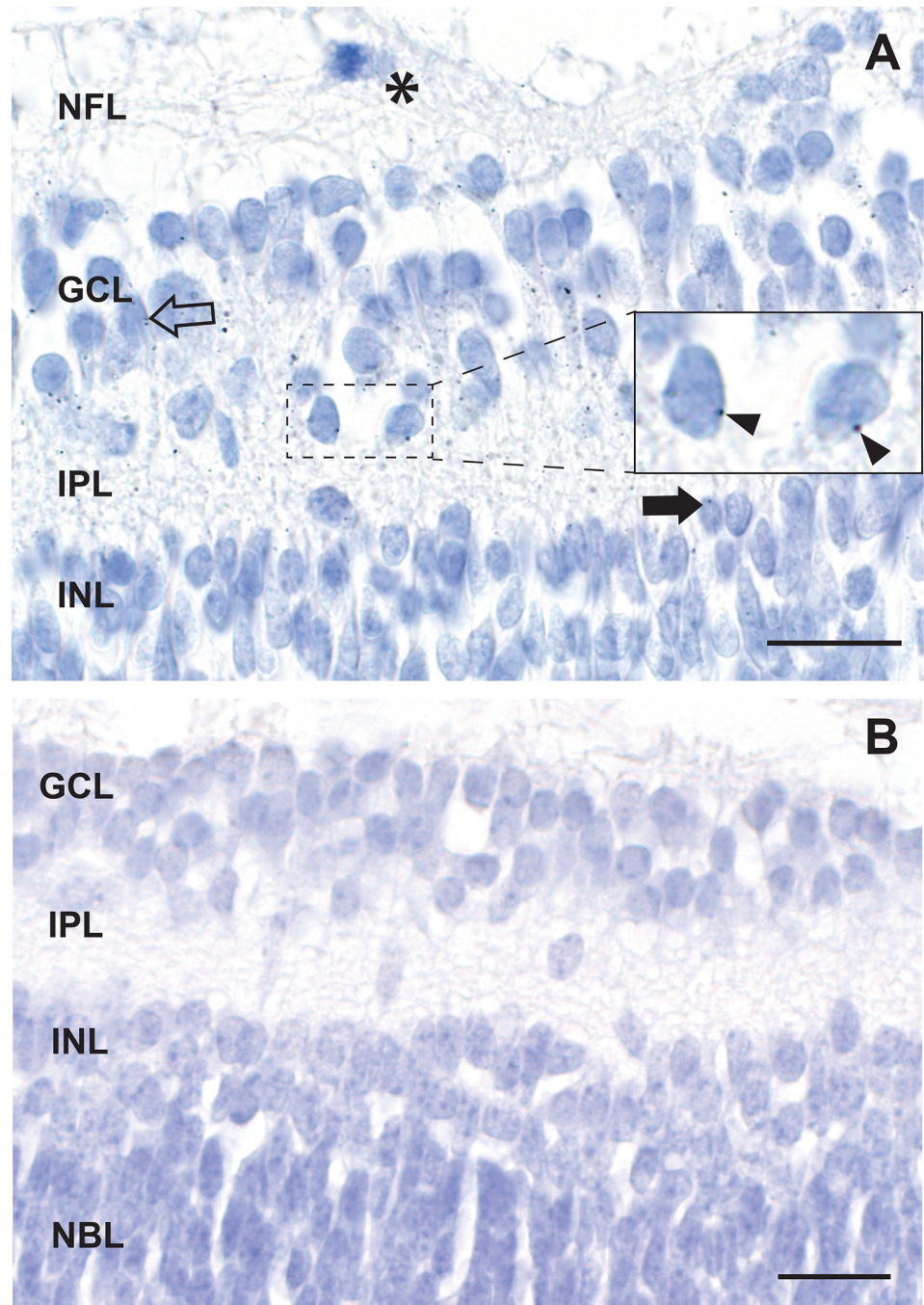


Fig 4. Mercury in the inner retina. A. AMG grains are attached to the nuclear membranes of scattered ganglion cells (eg, arrowheads in inset) and in endothelial cells (open arrow). A few AMG grains are present in the inner plexiform layer, and in nuclear membranes (eg, closed arrow) and endothelial cells of the inner nuclear layer. A mitosis (asterisk) is present in the nerve fibre layer. B. No AMG grains are seen in the cells of the inner retina in a neonatal mouse that had not been exposed to prenatal mercury vapor. NFL: nerve fibre layer, GCL: ganglion cell layer, IPL: inner plexiform layer, INL: inner nuclear layer, NBL: neuroblast layer. AMG/hematoxylin, Bars = 20 μ m.

<https://doi.org/10.1371/journal.pone.0220859.g004>

vapor from amalgam dental fillings may play a toxic role in the human retina, since people with amalgam fillings appear to have reduced volumes of the ganglion cell and inner plexiform

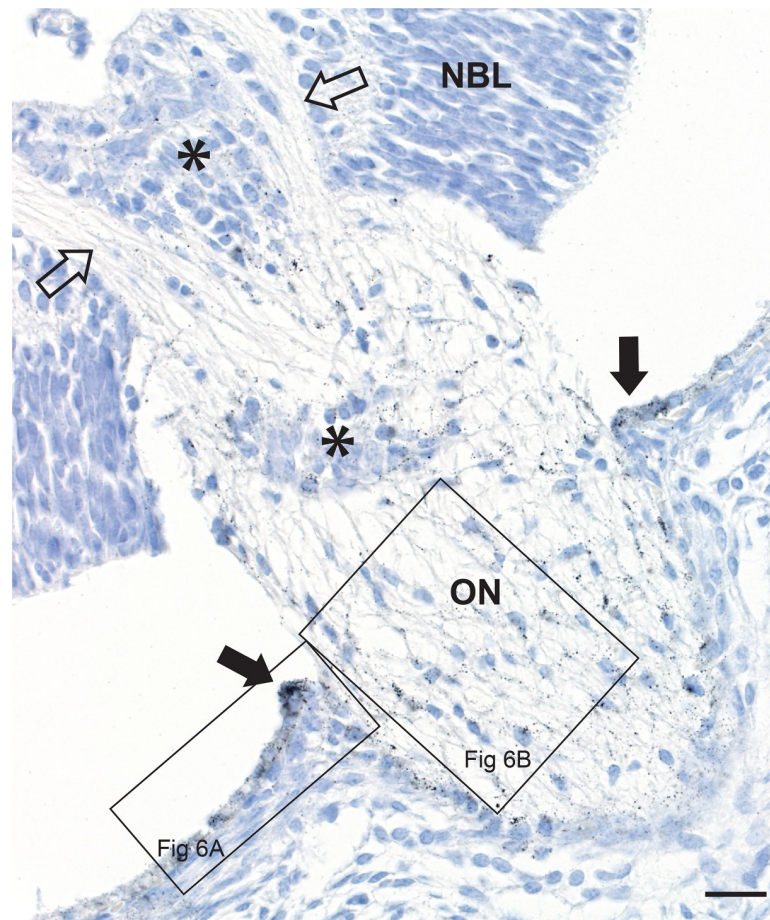


Fig 5. Mercury in the retinal pigment epithelium and optic nerve head. In a mouse exposed to mercury vapor, two nerve fibre bundles (open arrows) descend from the retinal nerve fibre layer into the optic nerve (ON) head. Black AMG grains can be seen in the retinal pigment epithelium (closed arrows) adjacent to the optic nerve head (see Fig 6A for high power view), and within the optic nerve head itself (see Fig 6B for high power view). Remnants of hyaloid blood vessels are present (asterisks). NBL: neuroblast layer. AMG/hematoxylin, Bar = 20 μ m.

<https://doi.org/10.1371/journal.pone.0220859.g005>

layers (measured with optical coherence tomography) compared to controls [26]. Despite the different methods of absorption and excretion of the three forms of mercury [24], the tissue distribution of mercury in experimental animals is similar when administered as mercury vapor [19], organic mercury [27] or inorganic mercury [28].

Inorganic mercury is transported into the retinal pigment epithelium as a thiol-conjugate [29], which may help explain the marked uptake of mercury into the peripapillary retinal pigment epithelium in our mice. Since adult monkeys exposed to mercury vapor take up mercury into the retina and optic nerve [10], inner retinal cells and optic nerve glia may also contain the (as-yet unidentified) mercury transporters which are found in various cells throughout the body [30].

The mouse fetal retina may be more susceptible than the adult retina to mercury uptake since the blood-retinal barrier is still incomplete in the late fetal and early neonatal mouse [17] (Fig 1). Most of the developing mouse brain endothelial cells have developed blood-brain barriers by gestational day 15 [31], around the time our mice were exposed to mercury, but the blood-brain barrier develops at various times in the brain, so the optic nerve too may have an incomplete barrier at that time.

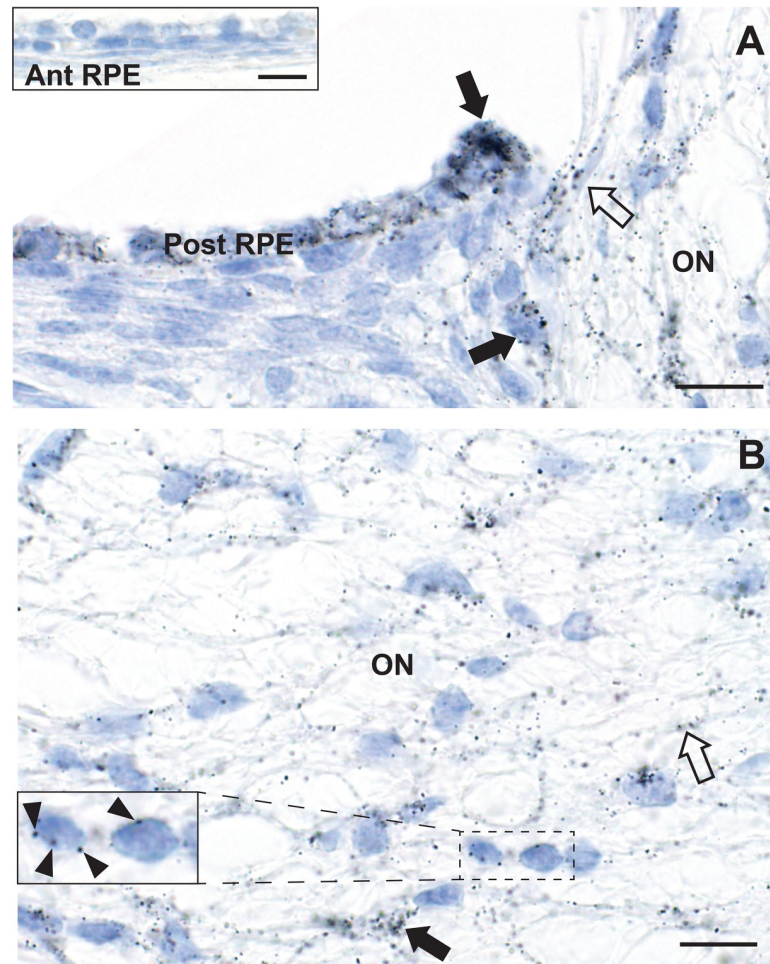


Fig 6. Mercury in the peripapillary retinal pigment epithelium and optic nerve head. A. Numerous AMG grains (closed arrows) are present in the peripapillary posterior retinal pigment epithelium (Post RPE), with decreasing amounts of mercury in the epithelium as the distance from the optic nerve (ON) head increases. AMG grains are seen in a capillary at the edge of the optic nerve (open arrow) and within the optic nerve head itself. Inset: no AMG grains are seen in the anterior retinal pigment epithelium (Ant RPE) of the same mouse (see Fig 2 for location). B. In the optic nerve head, AMG grains are attached to glial cell nuclear membranes (eg, arrowheads in the inset), glial cell processes (eg, closed arrow), and endothelial cells (eg, open arrow). AMG/hematoxylin, Bars = 10 μ m.

<https://doi.org/10.1371/journal.pone.0220859.g006>

The location of mercury in our mouse eyes and optic nerves are in regions that are involved in Alzheimer disease, Parkinson disease and amyotrophic lateral sclerosis (Table 1). Environmental exposure to mercury has been suggested to be a risk factor for these disorders [5,6], and the pathogenetic mechanisms that appear to underlie these neurodegenerative diseases are those shared by mercury toxicity, ie, free radical formation [32], epigenetic alterations [11] and DNA damage causing somatic mutations [33]. Our finding that mercury attaches to the nuclear membrane of cells fits with the preference of mercury for membranous structures in electron microscopic studies of mice exposed to mercury, which is possibly due to the large numbers of mercury-binding sulfhydryl groups in these membranes [34]. Mercury damages proteins, so the location of mercury in the nuclear membranes may explain how decreased transport of substances in and out of the nucleus via nuclear pores could underlie some neurodegenerative disorders [35].

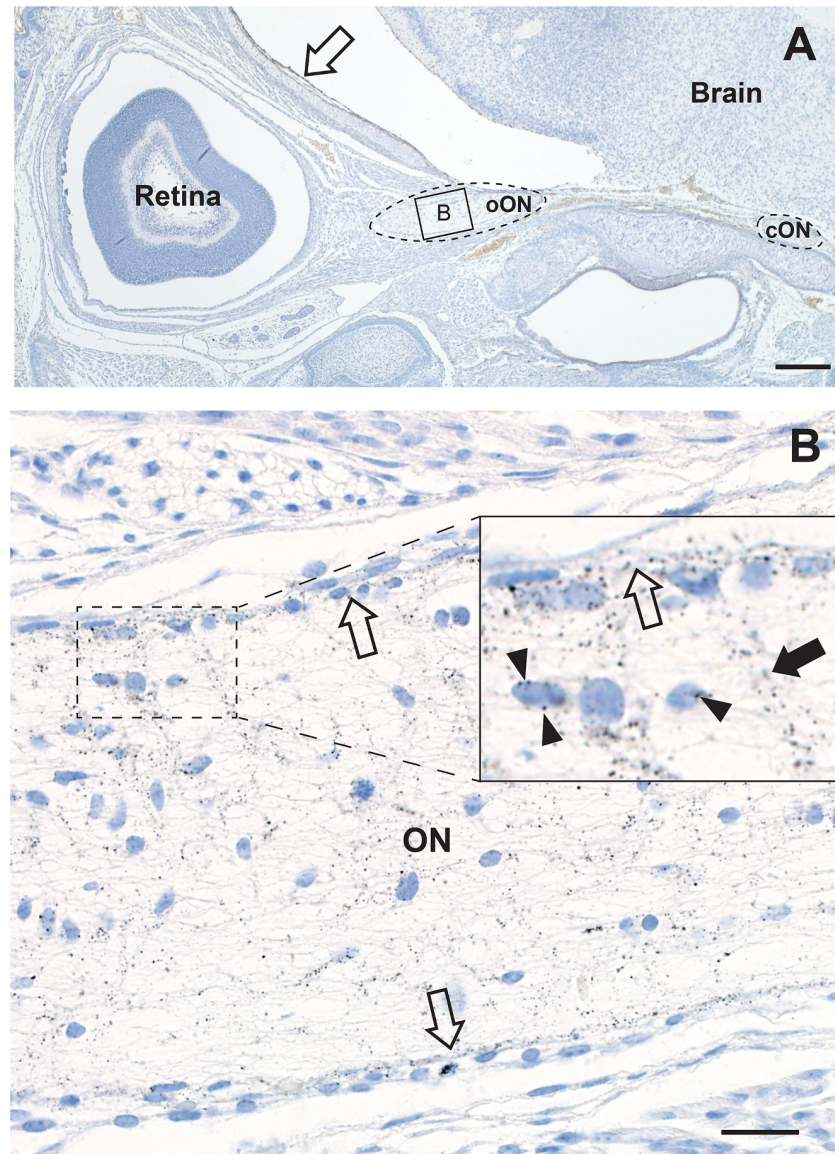


Fig 7. Mercury in the intra-orbital and intracranial optic nerves. A. The intra-orbital optic nerve (oON, dotted oval on left, box is at high power in panel B below) from one eye, and the intracranial optic nerve (cON, dotted oval on right) from the other eye, are present. The intracranial meningeal cells (open arrow) contain AMG grains. AMG/hematoxylin, Bar = 200 μ m. B. The intraorbital optic nerve contains numerous AMG grains, both in glial nuclear membranes (eg, arrowheads in inset) and in processes. AMG grains are prominent in endothelial cells of the peripheral pial plexus (all open arrows) and their branches (closed arrow in inset) that penetrate the optic nerve. AMG/hematoxylin, Bar = 20 μ m.

<https://doi.org/10.1371/journal.pone.0220859.g007>

The optic nerve is a frequent and early target for demyelination in multiple sclerosis [49], so here the preferential location of mercury in the optic nerve of our mice may be of relevance, since mercury provokes autoimmune reactions [54]. In addition, damage to the retinal inner nuclear layer has been described in multiple sclerosis [48], the same region in which mercury was found in our mice.

Age-related macular degeneration, a common cause of blindness in advancing age, has links with neurodegeneration since amyloid deposits like those in Alzheimer disease plaques are found in drusen, the sub-retinal epithelial cells seen in aging and macular degeneration

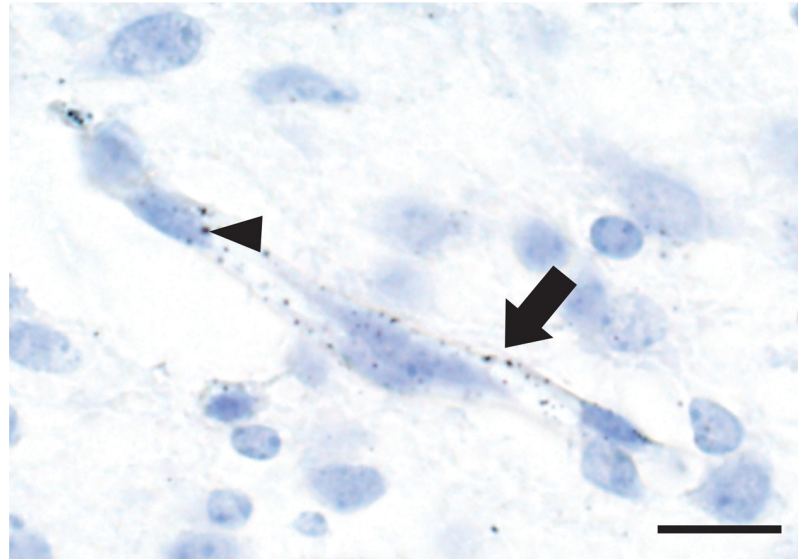


Fig 8. Mercury in brain endothelial cells. AMG grains are present in the endothelial cells (arrow) of a capillary within the thalamus. An occasional AMG grain is attached to an endothelial nuclear membrane (arrowhead). Surrounding neurons and glia do not contain mercury. AMG/hematoxylin, Bar = 10 μm.

<https://doi.org/10.1371/journal.pone.0220859.g008>

[55]. Mercury is found in retinal pigment epithelial cells [19,29,56,57] and so may play a part in the pathogenesis of macular degeneration. In macular degeneration, free radical formation [58] and epigenetic variations [59], both toxic actions of mercury, have been postulated to underlie retinal damage. The mouse eye does not have a well-developed macula [60,61] and so is not an ideal model to study macular degeneration, but peripapillary atrophy and disruption

Table 1. Disorders with damage to the retina and optic nerve, compared to fetal uptake of mercury.

Disorder	Fetal mercury uptake
Alzheimer disease/dementia	
Thin retina [36,37,38,39,40,41,42]	Inner retina
Peripapillary retinal atrophy [36]	Peripapillary RPE
Optic nerve damage [43]	Optic nerve
Parkinson disease	
Inner retina damage [44]	Inner retina
Amyotrophic lateral sclerosis	
Thin retina [45,46], inner nuclear layer p62 inclusions [47]	Inner retina
Multiple sclerosis	
Inner nuclear layer damage [48]	Inner retina
Optic neuritis [49]	Optic nerve
Age-related macular degeneration	
Peripapillary retinal atrophy [50,51]	Peripapillary RPE
Age-related peripapillary retinal atrophy	
Peripapillary retinal atrophy [52]	Peripapillary RPE
Neurodevelopmental disorders	
Thin nerve fibre layer [53]	Inner retina

RPE: retinal pigment epithelium

<https://doi.org/10.1371/journal.pone.0220859.t001>

of the retinal pigment epithelium are two features of macular degeneration [50,51] that could be explained by the uptake of mercury by the retinal pigment epithelium.

Peripapillary retinal atrophy alone is a frequent finding in aging [52]. The predilection in our mice for mercury to be taken up by the retinal pigment epithelium close to the optic nerve suggests that this region is particularly susceptible to toxic metals, and so may underlie this condition.

Endothelial cell uptake of mercury was prominent in the retina, optic nerve and brain of our fetal mice. The predisposition of endothelial cells to take up mercury has been noted before [62,63], and may lead to endothelial dysfunction [62,64]. This is of potential importance since mercury could play a role in the widespread dysfunction of the blood-brain barrier found in many adult neurodegenerative disorders [65,66,67] and in multiple sclerosis [68], and an increased permeability of brain capillaries might permit further toxicant entry into the brain with widespread consequences.

The present study has several limitations. (1) Mice were exposed to only one period of prenatal mercury exposure, in late gestation. This was because only in late gestation does the mouse placenta resemble that of the human chorioallantoic placenta, since the yolk sac supplies nutrients to the early mouse embryo until mid-gestation. Some toxins pass through the yolk sac that would be blocked by the chorioallantoic placenta, and some pass through the chorioallantoic placenta only, so studies on the early mouse embryo are not good models for human toxicity [69]. (2) We did not expose neonatal mice to the same prenatal dose of mercury vapor. However, when neonatal mice up to 10 postnatal days old were exposed to 10% of this dose, the distribution of mercury in the brain and spinal cord was the same as with the prenatal higher dose [12], suggesting the same pathways of mercury uptake are present in the late gestational and early postnatal time periods. (3) We were not able to assess the pathological consequences of mercury deposition in these cells, since all the gapless serial sections from each paraffin block were stained with autometallography, leaving no spare slides or tissue for analyses of mechanisms such as the generation of oxygen free radicals, autoimmune effects, or genetic or epigenetics changes. Free radical damage to cells containing mercury could be present in our mice, since we have shown oxidative damage to nucleic acids in the neurons of mice exposed to lower doses of mercury vapor than were used in the present experiment [70]. However, it is unlikely that pathogenic changes in this model would be seen so soon after mercury exposure, and in the absence of genetic susceptibilities that are thought to underlie human neurodegenerative disorders. (4) Autometallography demonstrates only inorganic mercury, and will not, for example, detect methylmercury. However, inorganic mercury is the proximate toxic agent for all forms of mercury [24], and so is arguably the most important form to identify to assess toxicity.

In conclusion, after pregnant mice are exposed to mercury vapor, mercury is taken up preferentially by the fetal inner retina, peripapillary retinal pigment epithelium, optic nerve and endothelial cells. This raises the possibility of a link between mercury exposure early in life and later-life neurodegenerative, demyelinating and retinal disorders in which these cells are affected. Epidemiological studies have so far not provided a convincing causal relationship between neurodegenerative diseases and toxic metals such as mercury from, for example, amalgam fillings [71,72], so advanced bioelemental mapping techniques on human eye and nervous system tissue will probably be required to obtain more evidence to support this hypothesis [73].

Acknowledgments

RP is supported by the Aimee Stacy Memorial and Ignacy Burnett bequests.

Author Contributions

Conceptualization: Roger Pamphlett.

Data curation: Roger Pamphlett, Stephen Kum Jew.

Formal analysis: Roger Pamphlett, Svetlana Cherepanoff.

Investigation: Roger Pamphlett, Stephen Kum Jew.

Methodology: Roger Pamphlett, Stephen Kum Jew.

Project administration: Roger Pamphlett.

Resources: Roger Pamphlett.

Supervision: Roger Pamphlett.

Writing – original draft: Roger Pamphlett.

Writing – review & editing: Roger Pamphlett, Stephen Kum Jew, Svetlana Cherepanoff.

References

1. London A, Benhar I, Schwartz M. The retina as a window to the brain—from eye research to CNS disorders. *Nat Rev Neurol*. 2013; 9: 44–53. <https://doi.org/10.1038/nrneurol.2012.227> PMID: 23165340
2. Monteiro M, Fernandes D, Apostolos-Pereira S, Cellegaro D. Quantification of retinal neural loss in patients with neuromyelitis optica and multiple sclerosis with or without optic neuritis using fourier-domain optical coherence tomography. *Invest Ophthalmol Vis Sci*. 2012; 53: 3959–3966. <https://doi.org/10.1167/iov.11-9324> PMID: 22589446
3. Tartaglione AM, Venerosi A, Calamandrei G. Early-Life Toxic Insults and Onset of Sporadic Neurodegenerative Diseases—an Overview of Experimental Studies. *Curr Top Behav Neurosci*. 2016; 29: 231–264. https://doi.org/10.1007/7854_2015_416 PMID: 26695168
4. Wang G, Walker SO, Hong X, Bartell TR, Wang X. Epigenetics and early life origins of chronic noncommunicable diseases. *J Adolesc Health*. 2013; 52: S14–21. <https://doi.org/10.1016/j.jadohealth.2012.04.019> PMID: 23332566
5. Bjorklund G, Dadar M, Mutter J, Aaseth J. The toxicology of mercury: Current research and emerging trends. *Environ Res*. 2017; 159: 545–554. <https://doi.org/10.1016/j.envres.2017.08.051> PMID: 28889024
6. Cariccio VL, Sama A, Bramanti P, Mazzon E. Mercury Involvement in Neuronal Damage and in Neurodegenerative Diseases. *Biol Trace Elem Res*. 2019; 187: 341–356. <https://doi.org/10.1007/s12011-018-1380-4> PMID: 29777524
7. El-Sherbeeny AM, Odom JV, Smith JE. Visual system manifestations due to systemic exposure to mercury. *Cutan Ocul Toxicol*. 2006; 25: 173–183. <https://doi.org/10.1080/15569520600860215> PMID: 16980243
8. Korbas M, Lai B, Vogt S, Gleber SC, Karunakaran C, Pickering IJ, et al. Methylmercury targets photoreceptor outer segments. *ACS Chem Biol*. 2013; 8: 2256–2263. <https://doi.org/10.1021/cb4004805> PMID: 23957296
9. Ekinci M, Ceylan E, Keles S, Cagatay HH, Apil A, Tanyildiz B, et al. Toxic effects of chronic mercury exposure on the retinal nerve fiber layer and macular and choroidal thickness in industrial mercury battery workers. *Med Sci Monit*. 2014; 20: 1284–1290. <https://doi.org/10.12659/MSM.890756> PMID: 25056093
10. Warfvinge K, Bruun A. Mercury accumulation in the squirrel monkey eye after mercury vapour exposure. *Toxicology*. 1996; 107: 189–200. PMID: 8604479
11. Cardenas A, Rifas-Shiman SL, Agha G, Hivert MF, Litonjua AA, DeMeo DL, et al. Persistent DNA methylation changes associated with prenatal mercury exposure and cognitive performance during childhood. *Sci Rep*. 2017; 7: 288. <https://doi.org/10.1038/s41598-017-00384-5> PMID: 28325913
12. Pamphlett R, Kum Jew S. Mercury vapor uptake into the nervous system of developing mice. *Neurotoxicol Teratol*. 2001; 23: 191–196. PMID: 11348837
13. Solan TD, Lindow SW. Mercury exposure in pregnancy: a review. *J Perinat Med*. 2014; 42: 725–729. <https://doi.org/10.1515/jpm-2013-0349> PMID: 24698820

14. Danscher G, Stoltenberg M, Juhl S. How to detect gold, silver and mercury in human brain and other tissues by autometallographic silver amplification. *Neuropathol Appl Neurobiol*. 1994; 20: 454–467. <https://doi.org/10.1111/j.1365-2990.1994.tb00996.x> PMID: 7845531
15. Pamphlett R, Png FY. Shrinkage of motor axons following systemic exposure to inorganic mercury. *J Neuropathol Exp Neurol*. 1998; 57: 360–366. <https://doi.org/10.1097/00005072-199804000-00009> PMID: 9600230
16. Smith RS, Kao WWY, John SWM (2002) Ocular Development. In: Smith RS, John SWM, Nishina PM, Sundberg JP, editors. *Systematic Evaluation of the Mouse Eye Anatomy, Pathology, and Biomethods*. Boca Raton: CRC Press. pp. 45–63.
17. Chow BW, Gu C. Gradual Suppression of Transcytosis Governs Functional Blood-Retinal Barrier Formation. *Neuron*. 2017; 93: 1325–1333 e1323. <https://doi.org/10.1016/j.neuron.2017.02.043> PMID: 28334606
18. Khayat A, Dencker L. Whole body and liver distribution of inhaled mercury vapor in the mouse: influence of ethanol and aminotriazole pretreatment. *J Appl Toxicol*. 1983; 3: 66–74. PMID: 6886298
19. Khayat A, Dencker L. Organ and cellular distribution of inhaled metallic mercury in the rat and Marmoset monkey (*Callithrix jacchus*): influence of ethyl alcohol pretreatment. *Acta Pharmacol Toxicol (Copenh)*. 1984; 55: 145–152.
20. Korbas M, Blechinger SR, Krone PH, Pickering IJ, George GN. Localizing organomercury uptake and accumulation in zebrafish larvae at the tissue and cellular level. *Proc Natl Acad Sci U S A*. 2008; 105: 12108–12112. <https://doi.org/10.1073/pnas.0803147105> PMID: 18719123
21. Clarkson TW, Magos L, Greenwood MR. The transport of elemental mercury into fetal tissues. *Biol Neonate*. 1972; 21: 239–244. <https://doi.org/10.1159/000240512> PMID: 4656187
22. Yoshida M. Placental to fetal transfer of mercury and fetotoxicity. *Tohoku J Exp Med*. 2002; 196: 79–88. <https://doi.org/10.1620/tjem.196.79> PMID: 12498319
23. Sakamoto M, Tatsuta N, Chan HM, Domingo JL, Murata K, Nakai K. Brain methylmercury uptake in fetal, neonate, weanling, and adult rats. *Environ Res*. 2018; 167: 15–20. <https://doi.org/10.1016/j.envres.2018.06.038> PMID: 30005196
24. Clarkson TW. The toxicology of mercury. *Crit Rev Clin Lab Sci*. 1997; 34: 369–403. <https://doi.org/10.3109/10408369708998098> PMID: 9288445
25. Yoshida M, Satoh H, Sumi Y. Effect of ethanol pretreatment on mercury distribution in organs of fetal guinea pigs following in utero exposure to mercury vapor. *Toxicology*. 1997; 119: 193–201. PMID: 9152015
26. Bilak S, Onderci M, Simsek A. Evaluation of amalgam-related retinal neurotoxicity with optical coherence tomography findings. *Hum Exp Toxicol*. 2019; Epub date: 13 Apr 2019. <https://doi.org/10.1177/0960327119842637> PMID: 30977404
27. Berlin M, Ullberg S. Accumulation and retention of mercury in the mouse. III. An autoradiographic comparison of methylmercuric dicyandiamide with inorganic mercury. *Arch Environ Health*. 1963; 6: 610–616. PMID: 13970885
28. Berlin M, Ullberg S. Accumulation and retention of mercury in the mouse. I. An autoradiographic study after a single intravenous injection of mercuric chloride. *Arch Environ Health*. 1963; 6: 589–601. PMID: 13970883
29. Bridges CC, Battle JR, Zalups RK. Transport of thiol-conjugates of inorganic mercury in human retinal pigment epithelial cells. *Toxicol Appl Pharmacol*. 2007; 221: 251–260. <https://doi.org/10.1016/j.taap.2007.03.004> PMID: 17467761
30. Bridges CC, Zalups RK. Mechanisms involved in the transport of mercuric ions in target tissues. *Arch Toxicol*. 2017; 91: 63–81. <https://doi.org/10.1007/s00204-016-1803-y> PMID: 27422290
31. Blanchette M, Daneman R. Formation and maintenance of the BBB. *Mech Dev*. 2015; 138 Pt 1: 8–16. <https://doi.org/10.1016/j.mod.2015.07.007> PMID: 26215350
32. Lund BO, Miller DM, Woods JS. Mercury-induced H₂O₂ production and lipid peroxidation *in vitro* in rat kidney mitochondria. *Biochem Pharmacol*. 1991; 42 Suppl: S181–187.
33. Crespo-Lopez ME, Macedo GL, Pereira SI, Arrifano GP, Picanco-Diniz DL, do Nascimento JL, et al. Mercury and human genotoxicity: critical considerations and possible molecular mechanisms. *Pharmacol Res*. 2009; 60: 212–220. <https://doi.org/10.1016/j.phrs.2009.02.011> PMID: 19446469
34. Chang LW, Hartmann HA. Electron microscopic histochemical study on the localization and distribution of mercury in the nervous system after mercury intoxication. *Exp Neurol*. 1972; 35: 122–137. [https://doi.org/10.1016/0014-4886\(72\)90064-7](https://doi.org/10.1016/0014-4886(72)90064-7) PMID: 5026408
35. Fahrenkrog B, Harel A. Perturbations in Traffic: Aberrant Nucleocytoplasmic Transport at the Heart of Neurodegeneration. *Cells*. 2018; 7. <https://doi.org/10.3390/cells7120232> PMID: 30486313

36. Iseri PK, Altinas O, Tokay T, Yuksel N. Relationship between cognitive impairment and retinal morphological and visual functional abnormalities in Alzheimer disease. *J Neuro-Ophthalmol*. 2006; 26: 18–24. <https://doi.org/10.1097/01.wno.0000204645.56873.26> PMID: 16518161
37. Lu Y, Li Z, Zhang X, Ming B, Jia J, Wang R, et al. Retinal nerve fiber layer structure abnormalities in early Alzheimer's disease: evidence in optical coherence tomography. *Neurosci Lett*. 2010; 480: 69–72. <https://doi.org/10.1016/j.neulet.2010.06.006> PMID: 20609426
38. Fyfe I. Retinal nerve fibre layer thickness—a biomarker of early dementia? *Nat Rev Neurol*. 2018; 14: 449. <https://doi.org/10.1038/s41582-018-0044-5> PMID: 29995835
39. Berisha F, Fekete GT, Trempe CL, McMeel JW, Schepens CL. Retinal abnormalities in early Alzheimer's disease. *Invest Ophthalmol Vis Sci*. 2007; 48: 2285–2289. <https://doi.org/10.1167/iovs.06-1029> PMID: 17460292
40. Paquet C, Boissonnot M, Roger F, Dighiero P, Gil R, Hugon J. Abnormal retinal thickness in patients with mild cognitive impairment and Alzheimer's disease. *Neurosci Lett*. 2007; 420: 97–99. <https://doi.org/10.1016/j.neulet.2007.02.090> PMID: 17543991
41. Ko F, Muthy ZA, Gallacher J, Sudlow C, Rees G, Yang Q, et al. Association of Retinal Nerve Fiber Layer Thinning With Current and Future Cognitive Decline. *JAMA Neurol*. 2018; 75: 1198–1205. <https://doi.org/10.1001/jamaneurol.2018.1578> PMID: 29946685
42. Mutlu U, Colijn JM, Ikram MA, Bonnemaier PWM, Licher S, Wolters FJ, et al. Association of Retinal Neurodegeneration on Optical Coherence Tomography With Dementia A Population-Based Study. *JAMA Neurol*. 2018; 75: 1256–1263. <https://doi.org/10.1001/jamaneurol.2018.1563> PMID: 29946702
43. Sadun AA, Bassi CJ. Optic nerve damage in Alzheimer's disease. *Ophthalmology*. 1990; 97: 9–17. [https://doi.org/10.1016/s0161-6420\(90\)32621-0](https://doi.org/10.1016/s0161-6420(90)32621-0) PMID: 2314849
44. Hajee ME, March WF, Lazzaro DR, Wolintz AH, Shrier EM, Glazman S, et al. Inner retinal layer thinning in Parkinson disease. *Arch Ophthalmol*. 2009; 127: 737–741. <https://doi.org/10.1001/archophthalmol.2009.106> PMID: 19506190
45. Bhattacharya S, Mukherjee N, McBurney-Lin S, Kuo A, Bedlack R, Tseng H. Retinal thinning in amyotrophic lateral sclerosis patients without ophthalmic disease. *PLoS One*. 2017; 12. <https://doi.org/10.1371/journal.pone.0185242> PMID: 28945811
46. Hubers A, Muller HP, Dreyhaupt J, Bohm K, Lauda F, Tumani H, et al. Retinal involvement in amyotrophic lateral sclerosis: a study with optical coherence tomography and diffusion tensor imaging. *J Neural Transm*. 2016; 123: 281–287. <https://doi.org/10.1007/s00702-015-1483-4> PMID: 26582428
47. Fawzi AA, Simonett JM, Purta P, Moss HE, Lowry JL, Deng HX, et al. Clinicopathologic report of ocular involvement in ALS patients with C9orf72 mutation. *Amyotroph Lateral Scler Frontotemporal Degener*. 2014; 15: 569–580. <https://doi.org/10.3109/21678421.2014.951941> PMID: 25319030
48. Green AJ, McQuaid S, Hauser SL, Allen IV, Lyness R. Ocular pathology in multiple sclerosis: retinal atrophy and inflammation irrespective of disease duration. *Brain*. 2010; 133: 1591–1601. <https://doi.org/10.1093/brain/awq080> PMID: 20410146
49. Burton EV, Greenberg BM, Frohman EM. Optic neuritis: A mechanistic view. *Pathophysiology*. 2011; 18: 81–92. <https://doi.org/10.1016/j.pathophys.2010.04.009> PMID: 20472407
50. Cohen SY, Dubois L, Grenet T, Nghiem-Buffet S, Jung C, Fajnkuchen F, et al. Peripapillary Retinal Pigment Epithelium Changes in Age-Related Macular Degeneration. *Retina*. 2016; 36: 458–464. <https://doi.org/10.1097/IAE.0000000000000741> PMID: 26267678
51. Chang P, Tan A, Jaffe GJ, Fleckenstein M, Holz FG, Schmitz-Valckenberg S, et al. Analysis of Peripapillary Atrophy in Relation to Macular Geographic Atrophy in Age-Related Macular Degeneration. *Invest Ophthalmol Vis Sci*. 2016; 57: 2277–2282. <https://doi.org/10.1167/iovs.15-18629> PMID: 27127925
52. Manjunath V, Shah H, Fujimoto JG, Duker JS. Analysis of peripapillary atrophy using spectral domain optical coherence tomography. *Ophthalmology*. 2011; 118: 531–536. <https://doi.org/10.1016/j.ophtha.2010.07.013> PMID: 20920826
53. Rothman AL, Sevilla MB, Mangalesh S, Gustafson KE, Edwards L, Cotten CM, et al. Thinner Retinal Nerve Fiber Layer in Very Preterm Versus Term Infants and Relationship to Brain Anatomy and Neurodevelopment. *Am J Ophthalmol*. 2015; 160: 1296–1308 e1292. <https://doi.org/10.1016/j.ajo.2015.09.015> PMID: 26386157
54. Vas J, Monestier M. Immunology of mercury. *Ann N Y Acad Sci*. 2008; 1143: 240–267. <https://doi.org/10.1196/annals.1443.022> PMID: 19076354
55. Isas JM, Luibl V, Johnson LV, Kaye R, Wetzell R, Glabe CG, et al. Soluble and mature amyloid fibrils in drusen deposits. *Invest Ophthalmol Vis Sci*. 2010; 51: 1304–1310. <https://doi.org/10.1167/iovs.09-4207> PMID: 19892876
56. Toimela TA, Tahti H. Effects of mercuric chloride exposure on the glutamate uptake by cultured retinal pigment epithelial cells. *Toxicol In Vitro*. 2001; 15: 7–12. PMID: 11259864

57. Ulshafer RJ, Allen CB, Rubin ML. Distributions of elements in the human retinal pigment epithelium. *Arch Ophthalmol*. 1990; 108: 113–117. <https://doi.org/10.1001/archophth.1990.01070030119041> PMID: 2297318
58. Hollyfield JG, Bonilha VL, Rayborn ME, Yang XP, Shadrach KG, Lu L, et al. Oxidative damage-induced inflammation initiates age-related macular degeneration. *Nat Med*. 2008; 14: 194–198. <https://doi.org/10.1038/nm1709> PMID: 18223656
59. Porter LF, Saptarshi N, Fang Y, Rathi S, den Hollander AI, de Jong EK, et al. Whole-genome methylation profiling of the retinal pigment epithelium of individuals with age-related macular degeneration reveals differential methylation of the SKI, GTF2H4, and TNXB genes. *Clin Epigenetics*. 2019; 11: 6. <https://doi.org/10.1186/s13148-019-0608-2> PMID: 30642396
60. Huber G, Heynen S, Imsand C, vom Hagen F, Muehlfriedel R, Tanimoto N, et al. Novel rodent models for macular research. *PLoS One*. 2010; 5: e13403. <https://doi.org/10.1371/journal.pone.0013403> PMID: 20976212
61. Li T, Volland S, Esteve-Rudd J, Hoo J, Yee C, Williams DS. A Comparison of Some Organizational Characteristics of the Mouse Central Retina and the Human Macula. *PLoS One*. 2015; 10. <https://doi.org/10.1371/journal.pone.0125631> PMID: 25923208
62. Moller-Madsen B. Localization of mercury in CNS of the rat. V. Inhalation exposure to metallic mercury. *Arch Toxicol*. 1992; 66: 79–89. PMID: 1605734
63. Warfvinge K. Mercury distribution in the mouse brain after mercury vapour exposure. *Int J Exp Pathol*. 1995; 76: 29–35. PMID: 7734337
64. Wiggers GA, Pecanha FM, Briones AM, Perez-Giron JV, Miguel M, Vassallo DV, et al. Low mercury concentrations cause oxidative stress and endothelial dysfunction in conductance and resistance arteries. *Am J Physiol Heart Circ Physiol*. 2008; 295: H1033–H1043. <https://doi.org/10.1152/ajpheart.00430.2008> PMID: 18599595
65. Erickson MA, Banks WA. Blood-brain barrier dysfunction as a cause and consequence of Alzheimer's disease. *J Cereb Blood Flow Metab*. 2013; 33: 1500–1513. <https://doi.org/10.1038/jcbfm.2013.135> PMID: 23921899
66. Gray MT, Woulfe JM. Striatal blood-brain barrier permeability in Parkinson's disease. *J Cereb Blood Flow Metab*. 2015; 35: 747–750. <https://doi.org/10.1038/jcbfm.2015.32> PMID: 25757748
67. Garbuzova-Davis S, Sanberg PR. Blood-CNS barrier impairment in ALS patients versus an animal model. *Front Cell Neurosci*. 2014; 8: 21. <https://doi.org/10.3389/fncel.2014.00021> PMID: 24550780
68. Ortiz GG, Pacheco-Moises FP, Macias-Islas MA, Flores-Alvarado LJ, Mireles-Ramirez MA, Gonzalez-Renovato ED, et al. Role of the blood-brain barrier in multiple sclerosis. *Arch Med Res*. 2014; 45: 687–697. <https://doi.org/10.1016/j.arcmed.2014.11.013> PMID: 25431839
69. Holson JF, Stump DG, Pearce LB, Watson RE, DeSesso JM. Mode of action: yolk sac poisoning and impeded histiotrophic nutrition—HBOC-related congenital malformations. *Crit Rev Toxicol*. 2005; 35: 739–745. PMID: 16417041
70. Pamphlett R, Slater M, Thomas S. Oxidative damage to nucleic acids in motor neurons containing mercury. *J Neurol Sci*. 1998; 159: 121–126. [https://doi.org/10.1016/s0022-510x\(98\)00161-0](https://doi.org/10.1016/s0022-510x(98)00161-0) PMID: 9741394
71. Rodriguez-Farre E, Testai E, Bruzell E, De Jong W, Schmalz G, Thomsen M, et al. The safety of dental amalgam and alternative dental restoration materials for patients and users. *Regul Toxicol Pharmacol*. 2016; 79: 108–109. <https://doi.org/10.1016/j.yrtph.2015.12.015> PMID: 26796567
72. Parkin Kullmann JA, Pamphlett R. A Comparison of Mercury Exposure from Seafood Consumption and Dental Amalgam Fillings in People with and without Amyotrophic Lateral Sclerosis (ALS): An International Online Case-Control Study. *Int J Environ Res Public Health*. 2018; 15. <https://doi.org/10.3390/ijerph15122874> PMID: 30558238
73. Pamphlett R, Bishop DP, Kum Jew S, Doble PA. Age-related accumulation of toxic metals in the human locus ceruleus. *PLoS One*. 2018; 13: e0203627. <https://doi.org/10.1371/journal.pone.0203627> PMID: 30231068