

CORRECTION

Correction: A Mutation in LTBP2 Causes Congenital Glaucoma in Domestic Cats (*Felis catus*)

Markus H. Kuehn, Koren A. Lipsett, Marilyn Menotti-Raymond, S. Scott Whitmore, Todd E. Scheetz, Victor A. David, Stephen J. O'Brien, Zhongyuan Zhao, Jackie K. Jens, Elizabeth M. Snella, N. Matthew Ellinwood, Gillian J. McLellan

In Fig 1, the numbers (n) of subjects are missing from the bars of the bar graph. Please see corrected [Fig 1](#) here.



 OPEN ACCESS

Citation: Kuehn MH, Lipsett KA, Menotti-Raymond M, Whitmore SS, Scheetz TE, David VA, et al. (2016) Correction: A Mutation in LTBP2 Causes Congenital Glaucoma in Domestic Cats (*Felis catus*). PLoS ONE 11(8): e0161517. doi:10.1371/journal.pone.0161517

Published: August 18, 2016

Copyright: This is an open access article, free of all copyright, and may be freely reproduced, distributed, transmitted, modified, built upon, or otherwise used by anyone for any lawful purpose. The work is made available under the [Creative Commons CC0](#) public domain dedication.

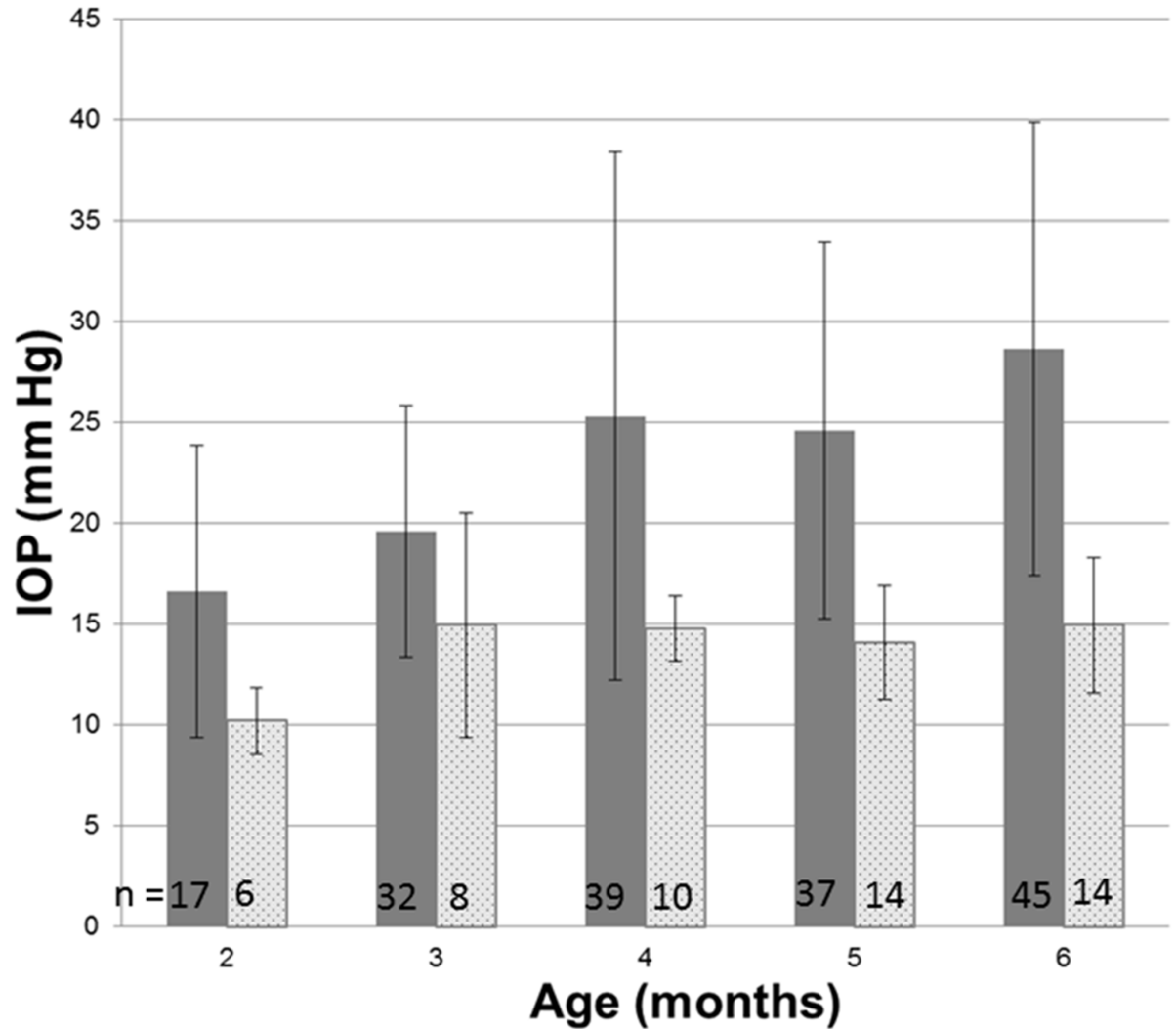


Fig 1. Intraocular pressure in glaucomatous and normal cats. Intraocular pressure measured by rebound tonometry (TonoVet, ICare oy, Finland) was significantly greater in PCG (solid bars) than in normal cats (patterned bars) at all ages from 2 months of age (ANOVA with Tukey-Kramer Multiple multiple comparisons post-test, $p < 0.05$). Error bars represent standard deviation. Numbers (n) of subjects in each age group are indicated on each column.

doi:10.1371/journal.pone.0161517.g001

Reference

1. Kuehn MH, Lipsett KA, Menotti-Raymond M, Whitmore SS, Scheetz TE, David VA, et al. (2016) A Mutation in LTBP2 Causes Congenital Glaucoma in Domestic Cats (*Felis catus*). PLoS ONE 11(5): e0154412. doi: [10.1371/journal.pone.0154412](https://doi.org/10.1371/journal.pone.0154412) PMID: [27149523](https://pubmed.ncbi.nlm.nih.gov/27149523/)