

RESEARCH ARTICLE

The neglected role of *Enterobius vermicularis* in appendicitis: A systematic review and meta-analysis

Ali Taghipour¹, Meysam Olfatifar², Ehsan Javanmard³, Mojtaba Norouzi¹, Hamed Mirjalali^{4*}, Mohammad Reza Zali²

1 Department of Parasitology, Faculty of Medical Sciences, Tarbiat Modares University, Tehran, Iran, **2** Gastroenterology and Liver Diseases Research Center, Research Institute for Gastroenterology and Liver Diseases, Shahid Beheshti University of Medical Sciences, Tehran, Iran, **3** Department of Parasitology and Mycology, School of Medicine, Shahid Beheshti University of Medical sciences, Tehran, Iran, **4** Foodborne and Waterborne Diseases Research Center, Research Institute for Gastroenterology and Liver Diseases, Shahid Beheshti University of Medical Sciences, Tehran, Iran

* hamedmirjalali@sbm.ac.ir, hamed_mirjalali@hotmail.com



OPEN ACCESS

Citation: Taghipour A, Olfatifar M, Javanmard E, Norouzi M, Mirjalali H, Zali MR (2020) The neglected role of *Enterobius vermicularis* in appendicitis: A systematic review and meta-analysis. PLoS ONE 15(4): e0232143. <https://doi.org/10.1371/journal.pone.0232143>

Editor: Paulo Lee Ho, Instituto Butantan, BRAZIL

Received: January 8, 2020

Accepted: April 7, 2020

Published: April 23, 2020

Copyright: © 2020 Taghipour et al. This is an open access article distributed under the terms of the [Creative Commons Attribution License](https://creativecommons.org/licenses/by/4.0/), which permits unrestricted use, distribution, and reproduction in any medium, provided the original author and source are credited.

Data Availability Statement: All relevant data are within the manuscript and its Supporting Information files.

Funding: The author(s) received no specific funding for this work.

Competing interests: The authors have declared that no competing interests exist.

Abbreviations: HDI, human development index; PRISMA, preferred reporting items for systematic reviews and meta-analysis; CI, confidence interval; OR, odds ratio.

Abstract

Although the main cause of appendicitis is unclear, infection with *Enterobius vermicularis* is suggested as a neglected risk factor. Since, there is no comprehensive analysis to estimate the prevalence of *E. vermicularis* in appendicitis; therefore, we conducted a global-scale systematic review and meta-analysis study to estimate the prevalence of *E. vermicularis* infection in appendicitis cases. PubMed, Scopus, Web of Science and Google Scholar databases were systematically searched for relevant studies published until 15 August 2019. Pooled prevalence of *E. vermicularis* infection was estimated using the random effects model. Data were classified based on the continents and countries. Moreover, subgroup analyses regarding the gender, the human development index (HDI), and income level of countries were also performed. Fifty-nine studies involving 103195 appendix tissue samples belonging to the individuals of appendicitis were included. The pooled prevalence of *E. vermicularis* infection was (4%, 95%CI, 2–6%), with the highest prevalence (8%, 95% CI: 0–36%) and lowest prevalence (2%, 95% CI: 1–4%) in Africa and Americas continents, respectively. With respect to countries, the lowest and highest prevalence rates were reported from Venezuela (<1%, 95% CI: 0–1%) and Nigeria (33%, 95% CI: 17–52%), respectively. Indeed, a higher prevalence was observed in females, as well as in countries with lower levels of income and HDI. Our findings indicate the relatively high burden of *E. vermicularis* infection in appendicitis cases. However, our findings suggest the great need for more epidemiological studies to depth understand overlaps between *E. vermicularis* infection and appendicitis in countries with lower HDI and income levels.

Introduction

Appendicitis is frequently reported from patients with severe abdominal pain requiring emergency surgery [1, 2]. According to the Global Burden of Disease (GBD) reports in 2015, approximately 11.6 million cases of appendicitis occurred with about 50100 deaths [3, 4]. The clinical manifestations of appendicitis commonly includes right lower abdominal pain, nausea, vomiting, and loss of appetite (anorexia) [5]. Despite recent progresses in antibiotic therapy, laparoscopic appendectomy has been remained a traditional treatment for acute appendicitis [6, 7].

There are various theories explaining the reasons of this disease; however, because of many factors contributed to appendicitis, the underlying cause is still unclear [1]. Interestingly, the role of infectious diseases in the etiology of acute appendicitis has remained controversial for more than one century [8, 9]. Some reports have spotlighted the probable relevance of appendicitis and infectious agents like *Fusobacterium* spp., [10] and herpes simplex virus [11]. Nevertheless, the nematode parasite, *Enterobius vermicularis*, has been proposed as a probable cause of appendicitis [12, 13].

E. vermicularis is a cosmopolitan parasite and one of the most common human-infecting helminths in temperate and cool climates, as well as developed countries [14, 15]. This parasite is usually transmitted through close-contact between infected and uninfected persons, ingestion and inhalation of the eggs [16]. Since, *E. vermicularis* has a simple transmission route, reinfection is one of the main causes of development of the infection. However, complete life cycle of the helminth, from egg to adult worm, usually takes 2 to 4 weeks [17]. Although *E. vermicularis* infection commonly presents with perianal pruritus [18], it has also been reported to be associated with chronic abdominal pain, urinary tract infection, salpingitis, eosinophilic ileocolitis and pelvic abscess [19–22]. Couple of possible hypotheses explained the correlation between *E. vermicularis* and appendicitis of which mostly suggested ectopic migration of the parasite [23, 24]. Occasionally, erratic migration of eggs and larvae can elicit granuloma formation in the appendix [24], kidney [25], peritoneal cavity [26], male urinary tract [27], and female genital tract [28] which may lead to misdiagnosis. In the case of appendicitis, release and accumulation of eggs from female *E. vermicularis* may lead to the obstruction and inflammation of the appendix [29].

During recent decades, many articles have been published on the epidemiology and correlation of *E. vermicularis* and appendicitis, worldwide. In this global systematic review and meta-analysis, we assessed the status of *E. vermicularis* infection in appendicitis cases.

Methods

Information sources and search strategy

This review was done according to the preferred reporting items for systematic reviews and meta-analysis (PRISMA) [30]. International databases (Scopus, PubMed, Web of Science and Google Scholar) were searched for literature regarding the prevalence of *E. vermicularis* in individuals with appendicitis (from their inception until August 15, 2019), relevant papers were found using the following search terms: (“*Enterobius vermicularis*” OR “*E. vermicularis*” OR “Enterobiasis” OR “Oxyure” OR “*Oxyuris vermicularis*” OR “Oxyuriasis” OR “Pinworm” OR “Roundworm” OR “Threadworm” OR “Seatworm”) AND (“Appendix” OR “Appendices” OR “Appendicitis” OR “Appendectomy”) AND/OR (“Prevalence” OR “Frequency”). The bibliographic list of the relevant studies and reviews were explored in depth to find other related literatures which were not found via database searching.

Eligibility criteria, study selection and data extraction

Literature was initially screened by title and abstract, and after duplicate removal, the full text of eligible entries was retrieved via online resources. Two trained investigators evaluated the eligibility (AT and MN), then any discrepancies were obviated by consensus and discussion with a third reviewer (HM). The final required data were extracted by two authors and rechecked by third author (HM), as follows: the first author, implementation and publication year, country, continent, gender, diagnostic method, study design, total sample size, and number of infected subjects in studies. In addition, we collected information on HDI (<http://hdr.undp.org/en/composite/HDI>) and income level (<https://datahelpdesk.worldbank.org/knowledgebase/articles/906519-world-bank-country-and-lendinggroups>) of each country.

Inclusion criteria for our systematic review and meta-analysis were: (1) Peer-reviewed original articles and short reports, without geographical and time limitations; (2) studies published with full text or abstracts in English; (3) Studies conducted until August 15, 2019; (4) having total sample size and positive samples in appendicitis cases (5); we selected the confirmed cases of *E. vermicularis* infection by histopathological methods, such as presence of eggs or larvae worms in appendix. Articles without any of aforementioned criteria including reviews, editorials and/or letters, those with confusing/unclear analyses, and those with a specific population (e.g. the general population and immunocompromised groups) were dismissed.

Data synthesis and statistical analysis

In the present study, all statistical analyses were conducted using Meta for packages of R software version 3.5.1. The prevalence of *E. vermicularis* infection in appendicitis cases at a 95% confidence interval (CI) was estimated using a random effect model. Heterogeneity between studies was assessed using I^2 methods. I^2 values of 25%, 50% and 75% were considered as low, moderate and high heterogeneity, respectively. The pooled estimates were stratified based on the continents and countries. Moreover, subgroup analyses were conducted according to gender, income level and HDI of countries. In order to investigate the possibility of publication bias during the analysis, Eggers regression was employed. A *P*-value of less than 0.05 was considered statistically significant.

Results

As shown in Fig 1, a total of 1944 papers were found following the initial search of databases and ultimately 59 articles from 24 countries out of five continents met the inclusion criteria in the systematic review and meta-analysis [31–89] (Fig 1, S1 Table). Totally, 103195 appendix tissue samples belonging to the appendicitis cases were evaluated for *E. vermicularis* infection from Dec 1939 to Aug 2019 of which 2983 (2.89%) patients were positive for the helminth. The main study characteristics, sample size, and positive rate of *E. vermicularis* infection in appendicitis cases are presented in Table 1.

Regarding the income level, 28, 24, six, and one studies were conducted in countries with high, upper middle, lower middle, and low levels of income, respectively. Considering the HDI, 28, 26, four, and one studies were performed in countries with very high, high, medium, and low levels of HDI. Thirteen studies had extractable data regarding the gender (including 8201 males and 8375 females). The random-effects model was used due to the presence of significant heterogeneity ($I^2 = 98\%$). Detecting publication bias using the Eggers regression revealed that publication bias was statistically very significant ($P < 0.000$).

The overall prevalence of a positive histopathological methods result for *E. vermicularis* infection in appendicitis cases was estimated to be (4%; 95%CI, 2–6%) (Fig 2 and Table 2). The highest and lowest global burdens of *E. vermicularis* infection were found in the continents

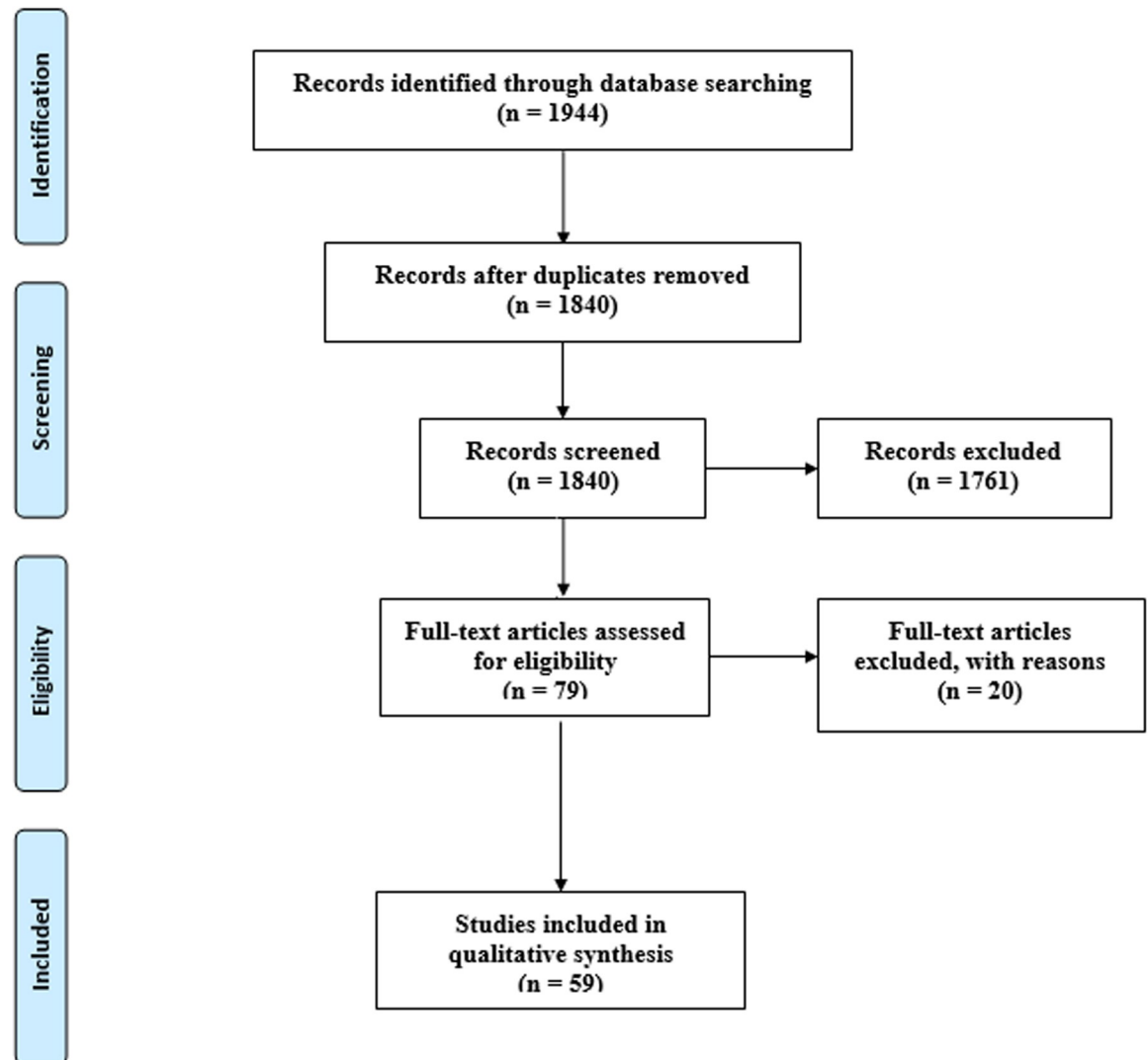


Fig 1. Flow diagram of the study design process.

<https://doi.org/10.1371/journal.pone.0232143.g001>

Africa (8%; 95%CI, 0–36%) and Americas (2%, 95%CI: 1–4%), respectively (Fig 2 and Table 2). Nigeria (33%, 95% CI: 17–52%) was identified as a country with the highest percentage of histopathological positive results while the lowest prevalence (<1%, 95% CI: 0–1%) was found in Venezuela (S1 Fig).

The prevalence map of *E. vermicularis* infections in appendicitis cases from different countries is presented in Fig 3. In a subgroup analysis by income level, the estimated prevalence of *E. vermicularis* infection in countries with high, upper middle, lower middle, and low levels of income was (3%, 95%CI: 2–4), (4%, 95%CI: 1–10%), (8%, 95%CI: 1–21%) and (1%, 95%CI: 1–3), respectively (Table 2, Fig 3 and S2 Fig). With regard to HDI, meta-analysis results revealed that the prevalence of *E. vermicularis* infection in countries with very high, high, medium, and low HDI was (3%, 95%CI: 2–4), (4%, 95% CI: 1–10%), (4%, 95% CI: 0–16%) and (33%, 95%CI: 17–52), respectively (Table 2 and S3 Fig).

Table 1. Main characteristics of all eligible studies reporting prevalence *E. vermicularis* in appendicitis.

First author/ Continent/ Ref	Publication year	Country	HDI	Income level	Total Sample	Infected Sample
Europe						
Duran-Jorda	1956	UK	Very high	High	691	52
Boulos and Cowie	1973	UK	Very high	High	293	8
Sterba and Vlcek	1984	Czech Republic	Very high	High	21916	1321
Budd and Armstrong	1987	UK	Very high	High	1529	38
Bredesen et al.	1988	Denmark	Very high	High	303	38
Wiebe	1991	Denmark	Very high	High	2267	93
Listorto et al.	1996	Italy	Very high	High	1093	14
Saxena et al.	2001	Germany	Very high	High	62	3
Yildirim et al.	2005	Turkey	High	Upper middle	104	4
Isik et al.	2007	Turkey	High	Upper middle	890	18
Aydin et al.	2007	Turkey	High	Upper middle	190	4
Sodergren et al.	2009	UK	Very high	High	1150	18
Karatepe et al.	2009	Turkey	High	Upper middle	5100	12
Ariyathenam et al.	2010	UK	Very high	High	498	13
Engin et al.	2010	Turkey	High	Upper middle	1969	7
Karaman et al.	2010	Turkey	High	Upper middle	916	23
Akbulut et al.	2011	Turkey	High	Upper middle	54	37
Mekhail et al.	2011	UK	Very high	High	268	8
Gialamas et al.	2012	Greece	Very high	High	1085	7
Yilmaz et al.	2013	Turkey	High	Upper middle	134	31
Ilhan et al.	2013	Turkey	High	Upper middle	3863	16
Yabanoglu et al.	2014	Turkey	High	Upper middle	57	15
Yabanoglu et al.	2014	Turkey	High	Upper middle	1159	15
Fleming et al.	2015	Ireland	Very high	High	182	13
Yildiz et al.	2015	Turkey	High	Upper middle	846	12
Akkapulu and Abdullazade	2016	Turkey	High	Upper middle	1446	9
Gorter et al.	2017	Netherlands	Very high	High	484	5
Altun et al.	2017	Turkey	High	Upper middle	660	9
Dincel et al.	2018	Turkey	High	Upper middle	1970	11
Unver et al.	2019	Turkey	High	Upper middle	2047	4
Tayfur and Balci	2019	Turkey	High	Upper middle	2400	22
Pehlivanoglu et al.	2019	Turkey	High	Upper middle	3222	24
Oztas et al.	2019	Turkey	High	Upper middle	48	37
Americas						
Botsford and Hudson	1939	USA	Very high	High	1343	71
Ashburn	1941	USA	Very high	High	1319	133
Wax and Cooper	1941	USA	Very high	High	1016	8
Dorfman et al.	1995	Venezuela	High	Upper middle	3465	14
Agarwala and Liu	2003	USA	Very high	High	317	1
Arca et al.	2004	USA	Very high	High	1549	21
Di et al.	2006	Argentina	Very high	High	186	2
da Silva et al.	2007	Brazil	High	Upper middle	1600	23
Maki et al.	2012	USA	Very high	High	913	16
Alemayehu et al.	2014	USA	Very high	High	3602	34
Spitale et al.	2017	Argentina	Very high	High	2000	65
Asia						

(Continued)

Table 1. (Continued)

First author/ Continent/ Ref	Publication year	Country	HDI	Income level	Total Sample	Infected Sample
Babekir and Devi	1990	United Arab Emirates	Very high	High	405	26
Dalimi and Khoshzaban	1993	Iran	High	Upper middle	1590	38
Fallah et al.	2006	Iran	High	Upper middle	5981	38
Sah and Bhadani	2006	Nepal	Medium	Low	624	9
Ramezani and Dehghani	2007	Iran	High	Upper middle	5048	144
Zakaria et al.	2013	Saudi Arabia	Very high	High	1600	45
Ahmed et al.	2015	Pakistan	Medium	Lower middle	2956	84
Zaghlool et al.	2015	Saudi Arabia	Very high	High	1536	4
Hamdona et al.	2016	Palestine	Medium	Lower middle	200	30
Africa						
Okolie et al.	2008	Nigeria	Low	Lower middle	27	9
Limaïem et al.	2015	Tunisia	High	Lower middle	1627	23
Zouari et al.	2018	Tunisia	High	Lower middle	540	53
Amer et al.	2018	Egypt	Medium	Lower middle	65	1
Oceania						
Dahlstrom and Macarthur	1994	Australia	Very high	High	1867	63
Lala and Upadhyay	2016	New Zealand	Very high	High	2923	109

Abbreviations: HDI: human development index.

<https://doi.org/10.1371/journal.pone.0232143.t001>

In a subgroup analysis by gender, the pooled prevalence in females 4.9% (2.9–8.1) was higher than males 2.7% (2.3–3.2) (Table 2), showing a statistically significant difference (OR, 0.47; 95%CI, 0.38–0.59) (Fig 4).

Discussion

Considering the fact that *E. vermicularis* infection is one of the important neglected causes of inflammation of appendix, it is necessary to discuss our knowledge about the prevalence rate of this infection in appendicitis cases. The presence of *E. vermicularis* infection in appendicitis was firstly reported by Fabrius in 1634 [90]. Since then, researchers have performed many studies on this line [36, 38, 91]. This systematic review is the first of that brings information to reveal global status of *E. vermicularis* infection in appendicitis cases. Our findings could be helpful for physicians and public health policy makers, especially in countries with lower health levels.

Our results indicated that 3005 tissue samples out of 103195 appendicitis cases were positive for *E. vermicularis* infection. We observed a geographical variation for the prevalence of *E. vermicularis* infection in appendicitis cases ranging from approximately 2% in the Americas to 8% in Africa. This variation in different continents could be resulted from lifestyle, sanitation status, culture, socioeconomic conditions, and climate [92–95]. For this purpose, we have done two sub-group analyses to evaluate the impact of HDI and income level parameters on the prevalence of *E. vermicularis*. As a result, low-income countries with lower HDI had higher prevalence of *E. vermicularis* than high-income countries with higher HDI.

In many territories, the prevalence of *E. vermicularis* has significantly decreased in recent decades due to screening programs and improved public health levels. For example, this reduction was observed in Turkey (from 45.9% to 16%) [96], Greece (from 22.1% to 5.2%) [97] and South Korea (from 17.1% to 7.9%) [98, 99]. However, although the global prevalence of helminthic infections reduced during the recent decades, it seems that regarding this fact that

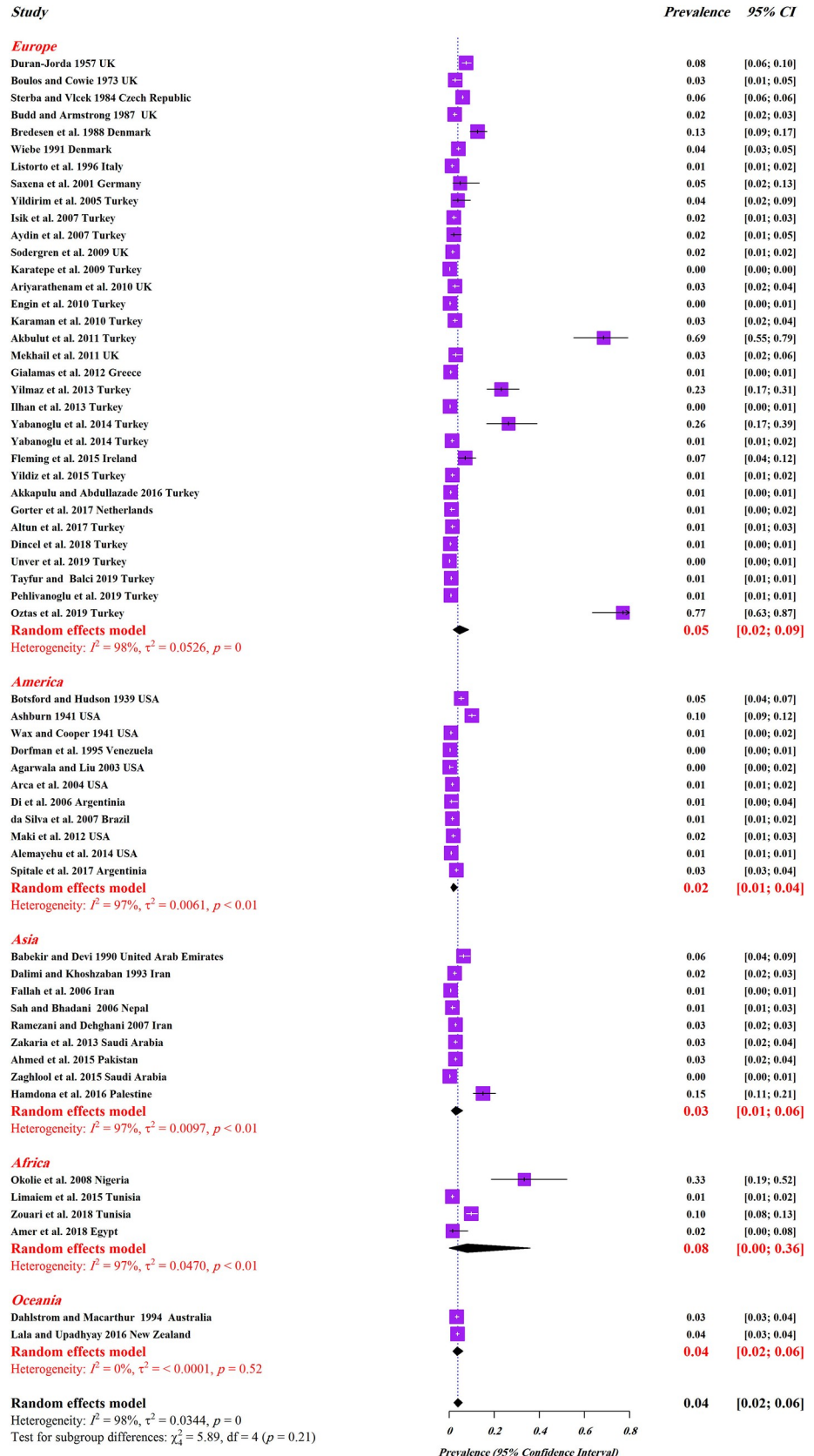


Fig 2. Forest plots for random-effects meta-analysis of *E. vermicularis* in appendicitis based on the prevalence in different continents.

<https://doi.org/10.1371/journal.pone.0232143.g002>

enterobiasis is a benign infection and most of infected subjects are asymptomatic, most of cases might be misdiagnosed during the screening programs.

The sub-group analysis showed that the prevalence of *E. vermicularis* in females was significantly higher than males (OR, 0.47; 95%CI, 0.38–0.59). Higher infection rates among females could be attributed to different behavioral patterns, as well as gender-based differences. Actually, housewife females usually work in kitchen and have close-contact to raw vegetables that makes them more prone to be infected with parasite (oo)cysts and eggs. On the other hand, it is interesting to mention that *E. vermicularis* was commonly seen in girls with average age of 12 years [36, 69] that makes them more susceptible to ectopic infections such as vulvitis and vaginitis.

Based on different aspects of histopathological variations, most of studies have shown a relatively high frequency of infiltration of neutrophils and purulent exudate as the most commonly observed findings [81, 100]. Moreover, eosinophilia, fecaliths, and the eggs in the lumen might be the microscopic reasons for appendicitis due to *E. vermicularis* [81, 101]. However, some studies concluded that mucosal infiltration by the eggs was not a factor for appendicitis [88]. Therefore, it should be considered that the role of *E. vermicularis* infection in appendicitis is still controversial [102]. Nevertheless, in appendicitis cases that no causative (probable) agents were detected except *E. vermicularis*, the neglected role of this helminth should be considered.

Table 2. Sub-group analysis of the prevalence of *E. vermicularis* based on continents, HDI and income level, and gender.

Variable/sub-groups	Number of studies	Sample size	Infected	Pooled prevalence (95% CI)	Heterogeneity	
					P value	I ²
Continent						
Europe	33	58896	1941	2.7 (1.8–4)	0.00	97.5
Americas	11	17310	388	1.6 (0.8–3.1)	0.00	97.2
Asia	9	19940	418	2.4 (1.4–4.1)	0.00	96.2
Africa	4	2259	86	6 (1.4–22.8)	0.00	96.7
Oceania	2	4790	172	3.6 (3.1–4.2)	0.52	0.00
Overall	59	103195	3005	3.3 (2.9–3.8)	0.00	97.2
HDI						
Very high	28	52397	2229	2.7 (2.1–3.5)	0.00	95.2
High	26	46926	643	2.1 (1.2–3.8)	0.00	97.8
Medium	4	3845	124	3.5 (1.1–10.9)	0.00	95.9
Low	1	27	9	33.3 (18.3–52.7)	1	0.00
Income level						
High	28	52397	2229	2.7 (2.1–3.5)	0.00	95.2
Upper middle	24	44759	567	2 (1.1–3.8)	0.00	97.8
Lower middle	6	5415	200	6.4 (2.6–14.7)	0.00	96.8
Low	1	624	9	1.4 (0.8–2.7)	1	0.00
Gender						
Male	11	8201	164	2.7 (2.3–3.2)	0.00	93.8
Female	13	8375	320	4.9 (2.9–8.1)	0.00	94.2

<https://doi.org/10.1371/journal.pone.0232143.t002>

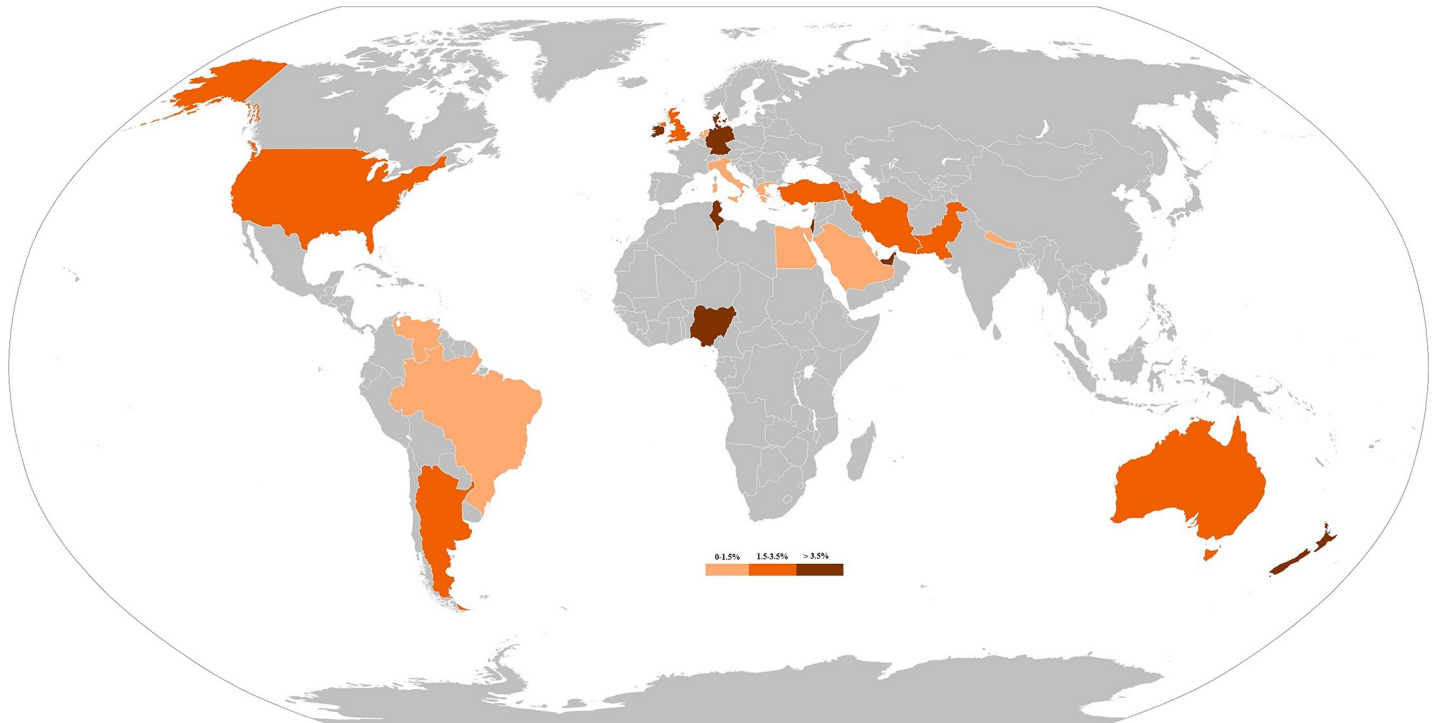


Fig 3. The prevalence of *E. vermicularis* appendicitis cases from different countries. This map shows that the prevalence rate of the parasite is mostly ranged < 3.5%. All figures were produced by the authors specifically for this manuscript. The raw map was downloaded from a free web source: https://commons.wikimedia.org/wiki/Atlas_of_the_world and edited with Photoshop cc by Ehsan Javanmard and Hamed Mirjalali.

<https://doi.org/10.1371/journal.pone.0232143.g003>

Study

- Duran-Jorda 1957 UK
- Gialamas et al. 2012 Greece
- Fleming et al. 2015 Ireland
- Altun et al. 2017 Turkey
- Tayfur and Balci 2019 Turkey
- Ramezani and Dehghani 2007 Iran
- Hamdona et al. 2016 Palestine
- Ahmed et al. 2015 Pakistan
- Sah and Bhadani 2006 Nepal
- Dahlstrom and Macarthur 1994 Australia
- Oztas et al. 2019 Turkey

Random effects model

Heterogeneity: $I^2 = 0\%$, $\tau^2 = 0.0501$, $p = 0.61$

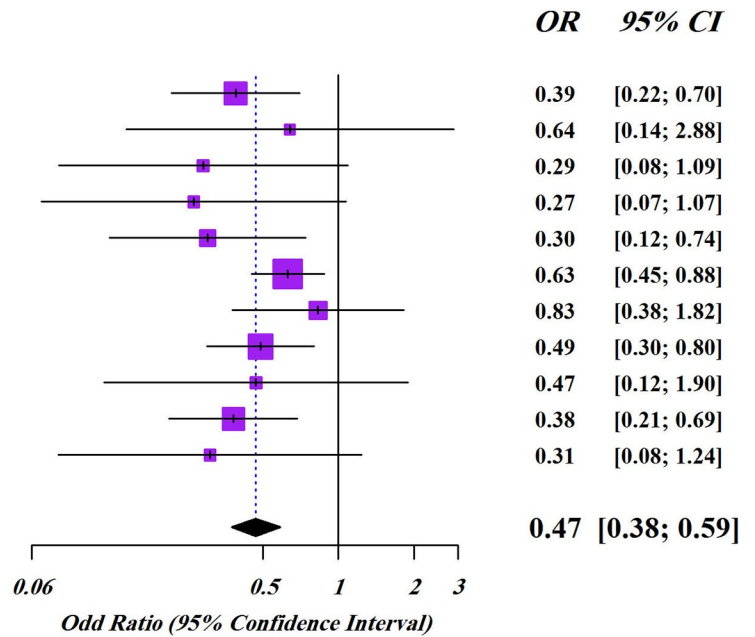


Fig 4. Forest plot pooled with random effects regarding the prevalence of *E. vermicularis* in appendicitis cases showing the OR and 95% CI by sub-group based on gender.

<https://doi.org/10.1371/journal.pone.0232143.g004>

The most important strengths of this systematic review and meta-analysis study are performing a comprehensive search of articles in four international databases, robust methodology, and conducting several subgroup analyses. Furthermore, this study has some limitations and the results presented here should be interpreted with regard to them including: 1) low number of researches in the case of the prevalence of *E. vermicularis* in appendicitis cases for many parts of the world and high heterogeneity. Moreover, in majority of the included articles, risk and demographic factors were not evaluated.

To minimize these limitations, we recommend that a standard questionnaire should be designed in order to perform a more comprehensive judgment on the risk factors including: gender, age, residence, education level, and occupation. Finally, we suggest that researchers should focus on the understanding the overlap between the presence of *E. vermicularis* and appendicitis in parts of the world, where there is a lack of information on the epidemiological aspects of *E. vermicularis* in appendicitis cases.

Conclusion

In conclusion, the results of the current study indicated that *E. vermicularis* is one of the common infectious agents that could be found in the appendix and may increase the risk of appendicitis. In addition, we concluded that HDI and socioeconomic conditions probably have direct effects on the prevalence of *E. vermicularis*, as well as appendicitis. This finding highlights the importance for considering the neglected role of parasites in some clinical cases such as appendicitis. Consequently, the possibility of intestinal parasitic infection of the appendix should be considered in the differential diagnosis of agents that may be involved in appendicitis. Moreover, it seems that stool and scotch adhesive tape examination for intestinal parasites should be incorporated into the routine screening of appendicitis, especially for helminths.

Supporting information

S1 Fig. Forest plots for random-effects meta-analysis of *E. vermicularis* in appendicitis based on the prevalence of the infection in different countries.

(JPG)

S2 Fig. Forest plots for random-effects meta-analysis of *E. vermicularis* in appendicitis based on the prevalence of the infection in different income levels.

(JPG)

S3 Fig. Forest plots for random-effects meta-analysis of *E. vermicularis* in appendicitis based on the prevalence of the infection in different HDI.

(JPG)

S1 Table. Prisma checklist.

(DOC)

Acknowledgments

We thank all colleagues of the Medical Parasitology Department, Tarbiat Modares University of Medical Sciences, and Foodborne and Waterborne Diseases Research Center, Research Institute for Gastroenterology and Liver Diseases, Shahid Beheshti University of Medical Sciences for their collaborations.

Author Contributions

Conceptualization: Ali Taghipour.

Data curation: Ehsan Javanmard, Mojtaba Norouzi, Mohammad Reza Zali.

Formal analysis: Meysam Olfatifar.

Investigation: Ali Taghipour.

Methodology: Ali Taghipour.

Supervision: Hamed Mirjalali.

Validation: Ali Taghipour.

Writing – original draft: Ali Taghipour.

Writing – review & editing: Hamed Mirjalali.

References

1. Humes D, Simpson J. Acute appendicitis. *BMJ*. 2006; 333(7567):530–4. <https://doi.org/10.1136/bmj.38940.664363.AE> PMID: 16960208
2. Prystowsky JB, Pugh CM, Nagle AP. Appendicitis. *Curr Problems Surg*. 2005; 42(10):694–742.
3. Vos T, Allen C, Arora M, Barber RM, Bhutta ZA, Brown A, et al. Global, regional, and national incidence, prevalence, and years lived with disability for 310 diseases and injuries, 1990–2015: a systematic analysis for the global burden of disease study 2015. *Lancet*. 2016; 388(10053):1545–602. [https://doi.org/10.1016/S0140-6736\(16\)31678-6](https://doi.org/10.1016/S0140-6736(16)31678-6) PMID: 27733282
4. Wang H, Naghavi M, Allen C, Barber RM, Bhutta ZA, Carter A, et al. Global, regional, and national life expectancy, all-cause mortality, and cause-specific mortality for 249 causes of death, 1980–2015: a systematic analysis for the global burden of disease study 2015. *Lancet*. 2016; 388(10053):1459–544. [https://doi.org/10.1016/S0140-6736\(16\)31012-1](https://doi.org/10.1016/S0140-6736(16)31012-1) PMID: 27733281
5. Martin RF. Acute appendicitis in adults: Clinical manifestations and differential diagnosis. Editado por Martin Weiser Up to date. 2014.
6. Mohamed A, Bhat N. Acute appendicitis dilemma of diagnosis and management. *Internet J Surg*. 2010; 23(2):1528–8242.
7. Styruud J, Eriksson S, Nilsson I, Ahlberg G, Haapaniemi S, Neovius G, et al. Appendectomy versus antibiotic treatment in acute appendicitis. a prospective multicenter randomized controlled trial. *World J Surg*. 2006; 30(6):1033. <https://doi.org/10.1007/s00268-005-0304-6> PMID: 16736333
8. Altemeier WA. The bacterial flora of acute perforated appendicitis with peritonitis: a bacteriologic study based upon one hundred cases. *Ann Surg*. 1938; 107(4):517.
9. Andersson R, Hugander A, Thulin A, NYSTRÖM PO, Olaison G. Clusters of acute appendicitis: further evidence for an infectious aetiology. *Int J Epidemiol*. 1995; 24(4):829–33. <https://doi.org/10.1093/ije/24.4.829> PMID: 8550282
10. Zhong D, Brower-Sinning R, Firek B, Morowitz MJ. Acute appendicitis in children is associated with an abundance of bacteria from the phylum *Fusobacteria*. *J Pediatr Surg*. 2014; 49(3):441–6. <https://doi.org/10.1016/j.jpedsurg.2013.06.026> PMID: 24650474
11. Katzoli P, Sakellaris G, Ergazaki M, Charissis G, Spandidos DA, Sourvinos G. Detection of herpes viruses in children with acute appendicitis. *J Clin Virol*. 2009; 44(4):282–6. <https://doi.org/10.1016/j.jcv.2009.01.013> PMID: 19233720
12. Mogensen K, Pahle E, Kowalski K. *Enterobius vermicularis* and acute appendicitis. *Acta Chir Scand*. 1985; 151(8):705–7.
13. Garza-Serna U, Ramos-Mayo A, Lopez-Garnica D, Lopez-Morales J, Diaz-Elizondo J, Flores-Villalba E. Eosinophilic acute appendicitis and intra-abdominal granuloma caused by *Enterobius vermicularis* in a pediatric patient. *Surg Infect Case Rep*. 2016; 1(1):103–5.
14. Wang S, Yao Z, Hou Y, Wang D, Zhang H, Ma J, et al. Prevalence of *Enterobius vermicularis* among preschool children in 2003 and 2013 in Xinxiang city, Henan province, Central China. *Parasite*. 2016; 23.

15. Moosazadeh M, Abedi G, Afshari M, Mahdavi SA, Farshidi F, Kheradmand E. Prevalence of *Enterobius vermicularis* among children in Iran: A systematic review and meta-analysis. *Osong Public Health Res Perspect*. 2017; 8(2):108. <https://doi.org/10.24171/j.phrp.2017.8.2.02> PMID: 28540154
16. Cranston I, Potgieter N, Mathebula S, Ensink JH. Transmission of *Enterobius vermicularis* eggs through hands of school children in rural South Africa. *Act Trop*. 2015; 150:94–6.
17. Friesen J, Bergmann C, Neuber R, Fuhrmann J, Wenzel T, Durst A, et al. Detection of *Enterobius vermicularis* in greater Berlin, 2007–2017: seasonality and increased frequency of detection. *Europ J Clin Microbiol Infect Dis*. 2019; 38(4):719–23. <https://doi.org/10.1007/s10096-019-03495-1> PMID: 30712227
18. Rawla P, Sharma S. *Enterobius Vermicularis* (Pinworm). StatPearls [Internet]: StatPearls Publishing; 2018.
19. Choudhury S, Kumar B, Pal D. *Enterobius vermicularis* infestation of urinary tract leading to recurrent urinary tract infection. *Trop Parasitol*. 2017; 7(2):119–21. https://doi.org/10.4103/tp.TP_22_17 PMID: 29114492
20. Ngui R, Ravindran S, Ong DBL, Chow TK, Low KP, Nureena ZS, et al. *Enterobius vermicularis* salpingitis seen in the setting of ectopic pregnancy in a Malaysian patient. *J Clin Microbiol*. 2014; 52(9):3468–70. <https://doi.org/10.1128/JCM.01191-14> PMID: 24989613
21. Peixoto A, Gonçalves R, Silva M, Gaspar R, Silva R, Portugal R, et al. Eosinophilic ileocolitis due to *Enterobius vermicularis* infection: a rare cause of anemia. *Int J Colorectal Dis*. 2016; 31(3):743–. <https://doi.org/10.1007/s00384-015-2239-1> PMID: 25976928
22. Mentessidou A, Theocharides C, Patoulias I, Panteli C. *Enterobius vermicularis*-associated pelvic inflammatory disease in a child. *J Pediat Adolescent Gynecol*. 2016; 29(2):e25–e7.
23. McDonald G, Hourihane DB. Ectopic *Enterobius vermicularis*. *Gut*. 1972; 13(8):621–6. <https://doi.org/10.1136/gut.13.8.621> PMID: 5077172
24. Tuncer AA, Boz H, Tuncer N, Embleton DB. A clinical case of acute abdomen caused by a pinworm in appendix: ultrasound images—a case report. *Curr Med Imag Rev*. 2018; 14(6):1017–9.
25. Serpytis M, Seinis D. Fatal case of ectopic enterobiasis: *Enterobius vermicularis* in the kidneys. *Scand J Urol Nephrol*. 2012; 46(1):70–2. <https://doi.org/10.3109/00365599.2011.609834> PMID: 21879805
26. Sun T, Schwartz NS, Sewell C, Lieberman P, Gross S. *Enterobius* egg granuloma of the vulva and peritoneum: review of the literature. *Am J Trop Med Hyg*. 1991; 45(2):249–53. <https://doi.org/10.4269/ajtmh.1991.45.249> PMID: 1877720
27. Zahariou A, Karamouti M, Papaioannou P. *Enterobius vermicularis* in the male urinary tract: a case report. *J Med Case Rep*. 2007; 1(1):137.
28. Nair GG, Balan P. Ovarian enterobiasis: a case report. *Int J Res Med Sci*. 2018; 6(3):1055.
29. Williams D, Dixon M. Sex, *Enterobius vermicularis* and the appendix. *British J Surg*. 1988; 75(12):1225–6.
30. Moher D, Liberati A, Tetzlaff J, Altman DG, Group P. Preferred reporting items for systematic reviews and meta-analyses: the PRISMA statement. *Int J Surg*. 2010; 8(5):336–41. <https://doi.org/10.1016/j.ijvsu.2010.02.007> PMID: 20171303
31. Duran-Jorda F. Appendicitis and *Enterobiasis* in Children: A histological study of 691 appendices. *Arch Dis Childhood*. 1957; 32(163):208.
32. Boulos P, Cowie A. Pinworm infestation of the appendix. *British J Surg*. 1973; 60(12):975–6.
33. Stěrba J, Vlcek M. Appendiceal enterobiasis—its incidence and relationships to appendicitis. *Folia Parasitol*. 1984; 31(4):311–8. PMID: 6510834
34. Budd J, Armstrong C. Role of *Enterobius vermicularis* in the aetiology of appendicitis. *British J Surg*. 1987; 74(8):748–9.
35. Bredesen J, Falensteen AL, Kristiansen V, Sørensen C, Kjersgaard P. Appendicitis and enterobiasis in children. *Act Chir Scand*. 1988; 154(10):585–7.
36. Wiebe B. Appendicitis and *Enterobius vermicularis*. *Scand J Gastroenterol*. 1991; 26(3):336–8. <https://doi.org/10.3109/00365529109025051> PMID: 1853157
37. Listorto G, Ferranti F, Mancini G, Pizzicannella G, Sablone M, Rossi M, et al. The role of *Enterobius vermicularis* in etiopathogenesis of appendicitis. *Minerva Chir*. 1996; 51(5):293–6. PMID: 9072738
38. Saxena AK, Springer A, Tsokas J, Willital GH. Laparoscopic appendectomy in children with *Enterobius vermicularis*. *Surg Laparo Endo Per*. 2001; 11(4):284–6.
39. Yildirim S, Nursal TZ, Tarim A, Kayaselcuk F, Noyan T. A rare cause of acute appendicitis: parasitic infection. *Scand J Infect Dis*. 2005; 37(10):757–9. <https://doi.org/10.1080/00365540510012161> PMID: 16191896

40. Isik B, Yilmaz M, Karadag N, Kahraman L, Sogutlu G, Yilmaz S, et al. Appendiceal *Enterobius vermicularis* infestation in adults. *Int Surg*. 2007; 92(4):221–5. PMID: [18050832](#)
41. Aydin Ö. Incidental parasitic infestations in surgically removed appendices: a retrospective analysis. *Diag Path*. 2007; 2(1):16.
42. Sodergren MH, Jethwa P, Wilkinson S, Kerwat R. Presenting features of *Enterobius vermicularis* in the vermiform appendix. *Scand J Gastroenterol*. 2009; 44(4):457–61. <https://doi.org/10.1080/00365520802624227> PMID: [19085426](#)
43. Karatepe O, Adas G, Tukenmez M, Battal M, Altioek M, Karahan SR. Parasitic infestation as cause of acute appendicitis. *G Chir*. 2009; 30(10):426–8. PMID: [19954582](#)
44. Ariyathenam A, Nachimuthu S, Tang T, Courtney E, Harris S, Harris A. *Enterobius vermicularis* infestation of the appendix and management at the time of laparoscopic appendectomy: Case series and literature review. *Int J Surg*. 2010; 8(6):466–9. <https://doi.org/10.1016/j.ijso.2010.06.007> PMID: [20637320](#)
45. Engin O, Calik S, Calik B, Yildirim M, Coskun G. Parasitic appendicitis from past to present in Turkey. *Iran J Parasitol*. 2010; 5(3):57–63. PMID: [22347256](#)
46. Karaman Ü, Türkmen E, Iraz M, Karataş T, Çolak C. Parasitosis in appendectomy cases. *Eur J Gen Med*. 2010; 7(3): 317–20.
47. Akbulut S, Tas M, Sogutcu N, Arikanoglu Z, Basbug M, Ulku A, et al. Unusual histopathological findings in appendectomy specimens: a retrospective analysis and literature review. *World J Gastroenterol*: WJG. 2011; 17(15):1961. <https://doi.org/10.3748/wjg.v17.i15.1961> PMID: [21528073](#)
48. Mekhail P, Naguib N, Yanni F, Izzidien A. Appendicitis in paediatric age group: correlation between preoperative inflammatory markers and postoperative histological diagnosis. *African J Paediat Surg*. 2011; 8(3):309.
49. Gialamas E, Papavramidis T, Michalopoulos N, Karayannopoulou G, Cheva A, Vasilaki O, et al. *Enterobius vermicularis*: a rare cause of appendicitis. *Türk Parazitol Derg*. 2012; 36(1):37.
50. Yilmaz M, Akbulut S, Kutluturk K, Sahin N, Arabaci E, Ara C, et al. Unusual histopathological findings in appendectomy specimens from patients with suspected acute appendicitis. *World J Gastroenterol*: WJG. 2013; 19(25):4015. <https://doi.org/10.3748/wjg.v19.i25.4015> PMID: [23840147](#)
51. İlhan E, Senlikci A, Kızanoglu H, Ustüner MA, Vardar E, Aykas A, et al. Do intestinal parasitic infestations in patients with clinically acute appendicitis increase the rate of negative laparotomy? Analysis of 3863 cases from Turkey. *Przeglad Gastroenterol*. 2013; 8(6):366.
52. Yabanoglu H, Caliskan K, Aytac HO, Turk E, Karagulle E, Kayaselcuk F, et al. Unusual findings in appendectomy specimens of adults: retrospective analyses of 1466 patients and a review of literature. *Iran Red Cres Med J*. 2014; 16(2).
53. Yabanoglu H, Aytaç HÖ, Türk E, Karagülle E, Çaliskan K, Belli S, et al. Parasitic infections of the appendix as a cause of appendectomy in adult patients. *Türk Parazitol Derg*. 2014; 38(1):12.
54. Fleming C, Kearney D, Moriarty P, Redmond H, Andrews E. An evaluation of the relationship between *Enterobius vermicularis* infestation and acute appendicitis in a paediatric population—A retrospective cohort study. *Int J Surg*. 2015; 18:154–8. <https://doi.org/10.1016/j.ijso.2015.02.012> PMID: [25771103](#)
55. Yıldız T, İlçe Z, Turan G, Bozdağ Z, Elmas B. Parasites in the etiology of pediatric appendicitis. *Türk Parazitol Derg*. 2015; 39(3):190.
56. Akkapulu N, Abdullazade S. Is *Enterobius vermicularis* infestation associated with acute appendicitis? *Eur J Traum Emerg Surg*. 2016; 42(4):465–70.
57. Gorter RR, van Amstel P, van der Lee JH, van der Voorn P, Bakx R, Heij HA. Unexpected findings after surgery for suspected appendicitis rarely change treatment in pediatric patients; results from a cohort study. *J Pediat Surg*. 2017; 52(8):1269–72. <https://doi.org/10.1016/j.jpedsurg.2017.02.012> PMID: [28302361](#)
58. Altun E, Avci V, Azatçam M. Parasitic infestation in appendicitis. A retrospective analysis of 660 patients and brief literature review. *Saud Med J*. 2017; 38(3):314.
59. Dincel O, Göksu M, Türk BA, Pehlivanoğlu B, İşler S. Incidental findings in routine histopathological examination of appendectomy specimens; retrospective analysis of 1970 patients. *Ind J Surg*. 2018; 80(1):48–53. <https://doi.org/10.1007/s12262-016-1557-z> PMID: [29581685](#)
60. Ünver N, Coban G, Arıcı DS, Buyukpınarbasılı N, Gucin Z, Malya FÜ, et al. Unusual histopathological findings in appendectomy specimens: a retrospective analysis of 2047 cases. *Int J Surg Path*. 2019; 27(2):142–6.
61. Tayfur M, Balci M. Pathological changes in appendectomy specimens including the role of parasites: A retrospective study of 2400 cases of acute appendicitis. *Nig J Clin Prac*. 2019; 22(2):270.

62. Pehlivanoglu B, Türk BA, Isler S, Özdas S, Abes M. Findings in appendectomies with enterobius vermicularis infection: pinworm is not a cause of appendicitis. *Turkiye Parazitol Derg.* 2019; 43(1):21–25. <https://doi.org/10.4274/tpd.galenos.2019.6177> PMID: 30938128
63. Öztaş T, Dursun A, Söğütçü N, Bilici S. Unusual histopathological findings in appendectomy specimens obtained from 1683 pediatric patients with suspected acute appendicitis. *Ind J Surg.* 2019; 81(4):344–9.
64. Botsford TW, Hudson HW Jr, Chamberlain JW. Pinworms and appendicitis. *New Eng J Med.* 1939; 221(24):933–6.
65. Ashburn L. Appendiceal oxyuriasis: Its incidence and relationship to appendicitis. *Am J Pathol.* 1941; 17(6):841. PMID: 19970601
66. Wax WV, Cooper NS. *Oxyuris vermiculans* appendicitis. The incidence of *Oxyuris vermicularis* in a series of 1016 cases of appendicitis. *Am J Surg.* 1941; 52(1):89–91.
67. Dorfman S, Talbot I, Torres R, Cardozo J, Sanchez M. Parasitic infestation in acute appendicitis. *Ann Trop Med Parasitol.* 1995; 89(1):99–101.
68. Agarwala N, Liu C. Laparoscopic appendectomy. *J Am Assoc Gynecol Laparoscop.* 2003; 10(2):166–8.
69. Arca MJ, Gates RL, Groner JI, Hammond S, Caniano DA. Clinical manifestations of appendiceal pinworms in children: an institutional experience and a review of the literature. *Pediat Surg Int.* 2004; 20(5):372–5.
70. Di LM, Berghenti M, Cocuzza C, Manfredini A, Sciascia V, Salmi R. Pinworm infestation of the appendix. *G Chir.* 2006; 27(6–7):269–71. PMID: 17062198
71. da Silva DF, da Silva RJ, da Silva MG, Sartorelli AC, Rodrigues MAM. Parasitic infection of the appendix as a cause of acute appendicitis. *Parasitol Res.* 2007; 102(1):99–102. <https://doi.org/10.1007/s00436-007-0735-0> PMID: 17851689
72. Maki AC, Slack P, Wiesenauer C. *Enterobius vermicularis*: a cause of acute appendicitis in children. *Am Surg.* 2012; 78(12):E523. PMID: 23265108
73. Alemayehu H, Snyder CL, Peter SDS, Ostlie DJ. Incidence and outcomes of unexpected pathology findings after appendectomy. *J Ped Surg.* 2014; 49(9):1390–3.
74. Spitale L, Pizzi R, Tomas A, Paez MR, Pizzi H. *Enterobius vermicularis* enteroparasite role in appendicitis cecal: enterobiasis and appendicitis. *Rev Facult Ciencias Med (Cordoba, Argentina).* 2017; 74(3):277–80.
75. Babekir A, Devi N. Analysis of the pathology of 405 appendices. *East Afric Med J.* 1990; 67(9):599–602.
76. Dalimi A, Khoshzaban F. Comparative study of two methods for the diagnosis of *Enterobius vermicularis* in the appendix. *J Helminthol.* 1993; 67(1):85–6. <https://doi.org/10.1017/s0022149x00012918> PMID: 8509624
77. Fallah E, Khalili A, Dehgani A, Mahdipoorzareh N, editors. A study on *Enterobius vermicularis* infection in a appendices removed by surgery in Tabriz hospitals. 11th Int Congress Parasitol (ICOPA XI); 2006.
78. Sah SP, Bhadani PP. *Enterobius vermicularis* causing symptoms of appendicitis in Nepal. *Trop Doctor.* 2006; 36(3):160–2.
79. Ramezani MA, Dehghani MR. Relationship between *Enterobius vermicularis* and incidence of acute appendicitis. *Southeast Asia J Trop Med Public Health.* 2007; 38(1):20–3.
80. Zakaria OM, Zakaria HM, Daoud MY, Al Wadaani H, Al Buali W, Al-Mohammed H, et al. Parasitic infestation in pediatric and adolescent appendicitis: a local experience. *Oman Med J.* 2013; 28(2):92. <https://doi.org/10.5001/omj.2013.25> PMID: 23599875
81. Ahmed MU, Bilal M, Anis K, Khan AM, Fatima K, Ahmed I, et al. The frequency of *Enterobius vermicularis* infections in patients diagnosed with acute appendicitis in Pakistan. *Glob J Health Sci.* 2015; 7(5):196–201. <https://doi.org/10.5539/gjhs.v7n5p196> PMID: 26156929
82. Zaghlool DA, Hassan AA, Ahmed MA, Faidah HS. Incidental parasitic infections in surgically removed appendices: A retrospective analysis. *J Egypt Soc Parasitol.* 2015; 240(2496):1–8.
83. Hamdona SM, Lubbad AM, Al-Hindi AI. Histopathological study of *Enterobius vermicularis* among appendicitis patients in Gaza strip, Palestine. *J Parasit Dis.* 2016; 40(1):176–83. <https://doi.org/10.1007/s12639-014-0472-0> PMID: 27065621
84. Okolie B, Okonko I, Ogun A, Adedeji A, Donbraye E, Nkang A, et al. Incidence and detection of parasite ova in appendix from patients with appendicitis in south-eastern Nigeria. *World J Agri Sci.* 2008; 4:795–802.

85. Limaïem F, Arfa N, Marsaoui L, Bouraoui S, Lahmar A, Mzabi S. Unexpected histopathological findings in appendectomy specimens: a retrospective study of 1627 cases. *Ind J Surg*. 2015; 77(3):1285–90.
86. Zouari M, Louati H, Abid I, Trabelsi F, Dhaou MB, Jallouli M, et al. *Enterobius vermicularis*: a cause of abdominal pain mimicking acute appendicitis in children. A retrospective cohort study. *Arch Iran Med*. 2018; 21(2):67–72. PMID: [29664657](https://pubmed.ncbi.nlm.nih.gov/29664657/)
87. Amer A, Saad A, Antonios S, Hasby E. Prevalence of parasitic infections in surgically removed appendices: parasitological and histopathological studies. *Helminthologia*. 2018; 55(1):33–44. <https://doi.org/10.1515/helm-2017-0056> PMID: [31662625](https://pubmed.ncbi.nlm.nih.gov/31662625/)
88. Dahlstrom J, Macarthur E. *Enterobius vermicularis*: a possible cause of symptoms resembling appendicitis. *Australia New Zealand J Surg*. 1994; 64(10):692–4.
89. Lala S, Upadhyay V. *Enterobius vermicularis* and its role in paediatric appendicitis: protection or predisposition? *ANZ J Surg*. 2016; 86(9):717–9. <https://doi.org/10.1111/ans.13464> PMID: [26990375](https://pubmed.ncbi.nlm.nih.gov/26990375/)
90. Fry GF, Moore JG. *Enterobius vermicularis*: 10000-year-old human infection. *Science*. 1969; 166(3913):1620–. <https://doi.org/10.1126/science.166.3913.1620> PMID: [4900959](https://pubmed.ncbi.nlm.nih.gov/4900959/)
91. Habashi R, Lisi MP. Acute appendicitis and *Enterobius vermicularis* infestation. *Canadian Med Assoc J*. 2019; 191(17):E477–E.
92. Javanmard E, Niyyati M, Ghasemi E, Mirjalali H, Aghdaei HA, Zali MR. Impacts of human development index and climate conditions on prevalence of *Blastocystis*: a systematic review and meta-analysis. *Act Trop*. 2018; 185:193–203.
93. Gündüz T, Demirel MM, İnceboz T, Tosun S, Yereci K. Prevalence of intestinal parasitosis in children with gastrointestinal symptoms associated with socio-economic conditions in Manisa region. *Türk Parazitolo Derg*. 2005; 29(4):264–7.
94. Taghipour A, Azimi T, Javanmard E, Pormohammad A, Olfatifar M, Rostami A, et al. Immunocompromised patients with pulmonary tuberculosis; a susceptible group to intestinal parasites. *Gastroenterol Hepatol Bed Bench*. 2018; 11(Suppl 1):S134. PMID: [30774820](https://pubmed.ncbi.nlm.nih.gov/30774820/)
95. Taghipour A, Tabarsi P, Sohrabi MR, Riahi SM, Rostami A, Mirjalali H, et al. Frequency, associated factors and clinical symptoms of intestinal parasites among tuberculosis and non-tuberculosis groups in Iran: a comparative cross-sectional study. *Trans Royal Soc Trop Med Hyg*. 2019; 113(5):234–41.
96. Degerli S, Malatyali E, Ozcelik S, Celiksoz A. Enterobiosis in Sivas, Turkey from past to present, effects on primary school children and potential risk factors. *Turk Parazitolo Derg*. 2009; 33:95–100.
97. Platsouka E, Stephansou T, Marselou-Kinti O. Frequency of *Enterobius vermicularis* in children from the area of central Greece. *Deltion Hellinikis Microbiol Eterial*. 1985; 30:51–9.
98. Yang Y, Kim S, Jung S, Huh S, Lee JH. Chemotherapeutic trial to control enterobiasis in schoolchildren. *Korea J Parasitol*. 1997; 35(4):265–9.
99. Kang S, Jeon HK, Eom KS, Park J-K. Egg positive rate of *Enterobius vermicularis* among preschool children in Cheongju, Chungcheongbuk-do, Korea. *Korea J Parasitol*. 2006; 44(3):247–9.
100. Mowlavi G, Massoud J, Mobedi I, Rezaian M, Mohammadi SS, Mostoufi N, et al. *Enterobius vermicularis*: a controversial cause of appendicitis. *Iran J Public Health*. 2004:27–31.
101. Gupta K, Solanki A, Vasishta R. Appendiceal neuroma: report of an elusive neuroma. *Trop Gastroenterol*. 2012; 32(4):332–3.
102. Surmont I, Liu L. Enteritis, eosinophilia, and *Enterobius vermicularis*. *Lancet*. 1995; 346(8983):1167.