

RESEARCH ARTICLE

The effectiveness of clove oil and two different cautery disbudding methods on preventing horn growth in dairy goat kids

Melissa N. Hempstead^{1,2}, Joseph R. Waas², Mairi Stewart³, Vanessa M. Cave¹, Amanda R. Turner¹, Mhairi A. Sutherland^{1*}

1 Animal Behaviour and Welfare, AgResearch Ltd., Hamilton, New Zealand, **2** School of Science, The University of Waikato, Hamilton, New Zealand, **3** GRNZ, Petone, Lower Hutt, New Zealand

These authors contributed equally to this work.

* Mhairi.Sutherland@agresearch.co.nz



OPEN ACCESS

Citation: Hempstead MN, Waas JR, Stewart M, Cave VM, Turner AR, Sutherland MA (2018) The effectiveness of clove oil and two different cautery disbudding methods on preventing horn growth in dairy goat kids. PLoS ONE 13(11): e0198229. <https://doi.org/10.1371/journal.pone.0198229>

Editor: Juan J. Loor, University of Illinois, UNITED STATES

Received: May 13, 2018

Accepted: October 30, 2018

Published: November 14, 2018

Copyright: © 2018 Hempstead et al. This is an open access article distributed under the terms of the [Creative Commons Attribution License](https://creativecommons.org/licenses/by/4.0/), which permits unrestricted use, distribution, and reproduction in any medium, provided the original author and source are credited.

Data Availability Statement: All relevant data are within the paper and its Supporting Information files.

Funding: This work was funded by the New Zealand Ministry of Business, Innovation and Employment (MBIE: Contract C10X1307 to MAS; Wellington, New Zealand) and the Dairy Goat Cooperative (DGC) Ltd. (Hamilton, New Zealand). Authors that received funding: MS and MAS. MBIE, DGC and AgResearch had no role in study design, data collection and analysis, interpretation of data,

Abstract

The effectiveness of clove oil and cautery disbudding on horn growth was evaluated in goat kids. The study used 243 Saanen doe kids (4±1 days old; mean±SD) on two goat farms that were disbudded with either (i) clove oil injection (CLOVE), (ii) a cautery iron and bud removed (BUDOFF), or (iii) a cautery iron with bud left intact (BUDON). Each kid received a different treatment per bud, which were balanced between buds (left/right) and randomly allocated. A trained observer monitored bud growth following treatment for 3 months recording either: N: no growth, H: normal horn, S: abnormal horn (scur), or SC: soft, fibrous lump (scorn). After the final observation, buds were assessed for the probability of detecting (i) success (no growth), (ii) scurs, (iii) horns or (iv) scorns [with 95% CI]. The probability of success for BUDOFF (0.77 [0.63, 0.87]) was higher than for BUDON (0.20 [0.11, 0.34]) and CLOVE (0.09 [0.04, 0.18]; $P \leq 0.05$). Furthermore, the probability of success for BUDON was higher than for CLOVE ($P \leq 0.05$). The probability of scurs was higher for CLOVE (0.72 [0.63, 0.80]) than BUDOFF (0.25 [0.17, 0.34]) and BUDON (0.30 [0.21, 0.39]; $P \leq 0.05$). There was no difference in the probability of scurs for BUDOFF and BUDON ($P > 0.05$). The probability of horns was higher for CLOVE (0.21 [0.15, 0.29]) than BUDON (0.02 [0.01, 0.06]; $P \leq 0.05$); horns were not observed for BUDOFF. The probability of scorns for BUDON, the only treatment that led to scorns, was 0.41 (0.25, 0.60). These results suggest that BUDOFF was more effective at preventing growth than CLOVE and BUDON and appears the most effective method, of the methods tested, for disbudding kids. Future research should explore other alternatives to cautery disbudding that may be both efficacious and cause less pain.

Introduction

Dairy goat kids are routinely disbudded, usually within the first week of life [1]; the practice involves the destruction of the horn buds to prevent horn growth. The predominant method

preparation of the manuscript or decision to publish. The DGC reviewed the manuscript prior to submission. AgResearch Ltd. (Hamilton, New Zealand) provided support in the form of salaries for authors [MAS, MS, MNH VMC, ART] and research materials. The specific roles of these authors are articulated in the 'author contributions' section.

Competing interests: The authors are commercially affiliated with the New Zealand Ministry of Business, Innovation and Employment (MBIE: Contract C10X1307; Wellington, New Zealand), the Dairy Goat Cooperative (DGC) Ltd. (Hamilton, New Zealand) and AgResearch Ltd. (Hamilton, New Zealand). The DGC reviewed the manuscript prior to submission. AgResearch Ltd. (Hamilton, New Zealand) provided support in the form of salaries for authors [MAS, MS, MNH VMC, ART] and research materials. This does not alter our adherence to PLOS ONE policies on sharing data and materials.

involves using a hot cauterly iron to cauterise and remove horn buds. Disbudding is carried out to reduce the risk of injury to other goats [2] and their human handlers, and allows for more space at the feed rail or in lying areas, due to not having horns [3]. Current disbudding methods for goat kids have been adapted from those used for calves, such as cauterly disbudding, caustic agents and surgical methods [4–6].

It is documented that cauterly disbudding causes pain and distress in goat kids as evidenced by intense and frequent vocalisations, leg shakes during the procedure [7], elevated plasma cortisol concentrations and increased frequencies of head shaking, rubbing and scratching post-disbudding [8–10]. Furthermore, complications associated with cauterly disbudding include second- or third-degree burns, inflammation and the potential for thermal injury to the skull and brain (causing necrosis), infection and an increased risk of mortality [11–13].

If disbudding of goat kids is not performed, then adult goats can be dehorned; this involves surgical removal of the horns, which creates an opening into the frontal sinus and causes more pain than disbudding [5]. It can also lead to complications such as prolonged healing, discharge/infection, inflammation, regrowth of horns, dehiscence or even death [14, 15]. Therefore, disbudding is the preferred method for preventing horn growth.

There is limited research on the efficacy of different disbudding methods (including cauterly disbudding) on horn or scur growth in goat kids or calves. Disbudding is considered successful if no horns or scurs grow (i.e. all horn bud tissue is destroyed). Scurs can be defined as distorted horn regrowth following disbudding [15]. Problems associated with scurs include being aesthetically unpleasing, breaking off easily causing open wounds and increasing the risk of infection and potential abnormal growth back towards the animal's head, requiring surgical removal. Cauterly disbudding can be performed by either (i) totally removing the ring of tissue containing the horn bud cells or (ii) cutting/burning a circular ring around the horn bud but leaving it intact. It is unclear which method of cauterly disbudding is most effective in preventing scurs or horns.

A recent study used the physiological [9] and behavioural [16] responses of dairy goat kids to evaluate alternatives to cauterly disbudding (i.e. caustic paste and cryosurgical disbudding, clove oil injection). Clove oil injection elicited a similar cortisol response and number of head shakes and scratches as cauterly disbudding, indicating a similar experience of pain [9, 16]. Even though the pain response to clove oil injection appeared to be similar to that generated by the cauterly iron, the clove oil method caused less tissue damage [9, 16]. Consequently, clove oil injection may result in faster healing times and lower rates of infection or skull or brain injury. Caustic paste and cryosurgical disbudding appeared to cause more pain than cauterly disbudding [9, 16], and therefore were not included as treatments in the present study.

Clove oil, which was traditionally used in dentistry as a topical analgesic and antiseptic [17], contains a high concentration of eugenol (i.e. 80–85%), which has been shown to cause cellular necrosis (and inflammation) in the oral mucosa of rats [18]; it can also be highly cytotoxic for human skin cells [19]. Recently, clove oil has been shown to cause local cellular necrosis of horn bud tissue resulting in arrested horn growth in calves [20] and goat kids [21]. Further research is required to evaluate the effect of clove oil on horn and scur growth in goat kids.

The objective of this study was to evaluate the effectiveness of clove oil injection and two methods of cauterly disbudding (i.e. horn buds removed vs. left intact) on horn bud growth in dairy goat kids. We predicted that clove oil injection would result in similar levels of horn and scur growth as cauterly disbudding, based on the success rates (100%) reported by others [21]. We also predicted that cauterly disbudding with horn buds removed, would result in less horn and scur growth than leaving the horn buds intact due to increased potential for complete cell destruction.

Materials and methods

This study was approved by the Ruakura Animal Ethics Committee (Protocol Number: 14213).

Pilot study

A pilot experiment was carried out to ensure that administration of clove oil into the horn bud had no detrimental effect on the skull and brain of goat kids before further studies were conducted. On a commercial dairy goat farm in the Waikato region of New Zealand, 10 Saanen doe kids were selected from unwanted stock based on age (i.e. 2–3 days old) in June 2017. The animals were injected with 0.2 mL of clove oil into each horn bud using the procedure described in Hempstead et al. [9, 16]. Kids were reared in a small barn separate from the farmer's replacement stock and fed using a 10 L bucket feeder with 6 teats. Two weeks after clove oil injection, 5 kids were euthanized by a veterinary surgeon. The remaining 5 kids were euthanized 1 week later (i.e. 3 weeks after clove oil injection) to assess the effects of clove oil over time. After euthanasia, the bodies were transported to a post mortem facility at the Ruakura Research Centre, in Hamilton, New Zealand, and gross examination was then performed by a veterinary pathologist.

Firstly, the skin over the head was visually assessed and then the skin was removed so that the outside of the skull could be examined. Next, the head was cut transversely, just caudal to the horn buds using a commercial meat band saw. The brain was removed from the front part of the skull and the inner surface was examined for evidence of damage (e.g., perforation, hyperaemia) or inflammation beneath the horn bud sites. The dorsal surface of both cerebral hemispheres beneath these sites, were examined for ulcerations.

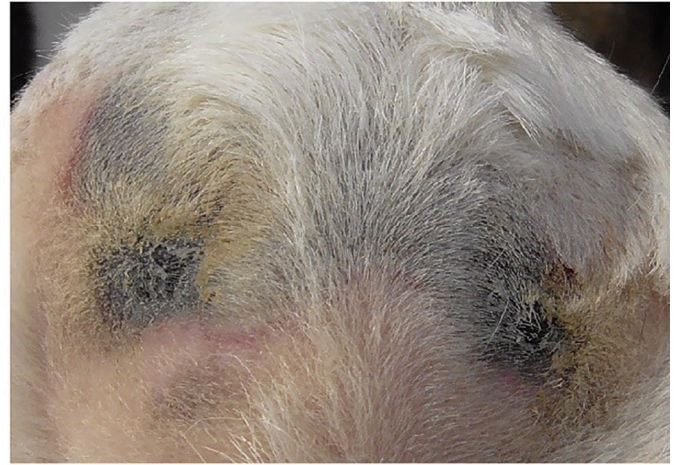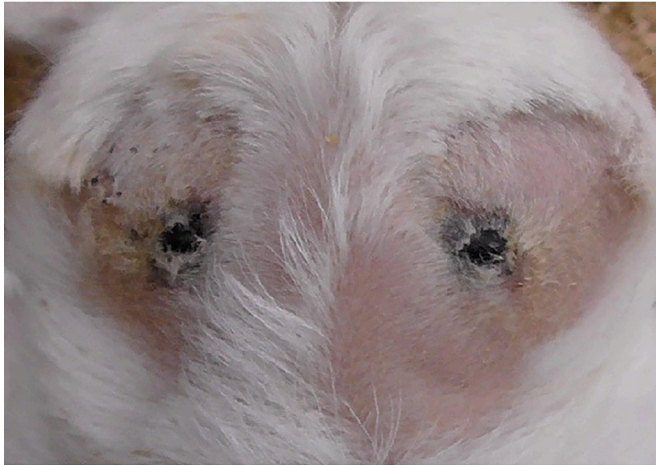Large black scabs covered the horn buds 2 weeks post-injection of clove oil. There were localised dark patches on the skull below the horn buds for the 5 kids euthanized 2 weeks after treatment, with no evidence of damage on the inside of the skull or the brain. At 3 weeks post-injection, patches of newly healed skin were observed as well as scurs in 3 out of the 5 kids. Discolouration of the skull beneath the horn buds was apparent in only one kid. There was no evidence of inflammation, perforation or infection of the skull, meninges or brain associated with the clove oil injection for any of the kids. Images of different stages of healing following clove oil injection are shown in Fig 1.

Animals and housing

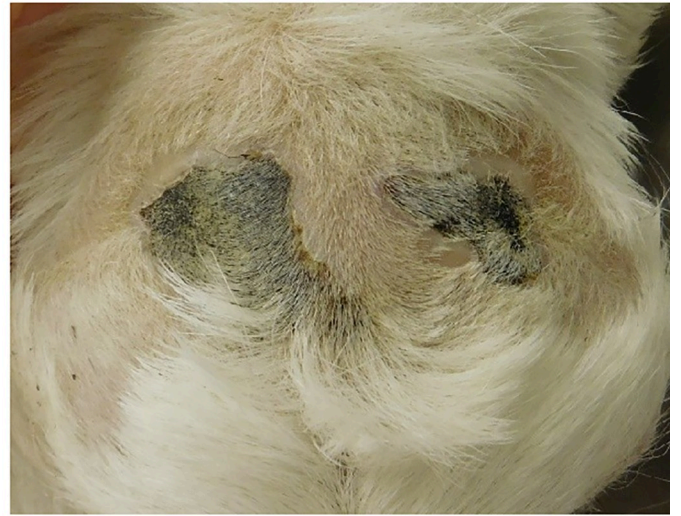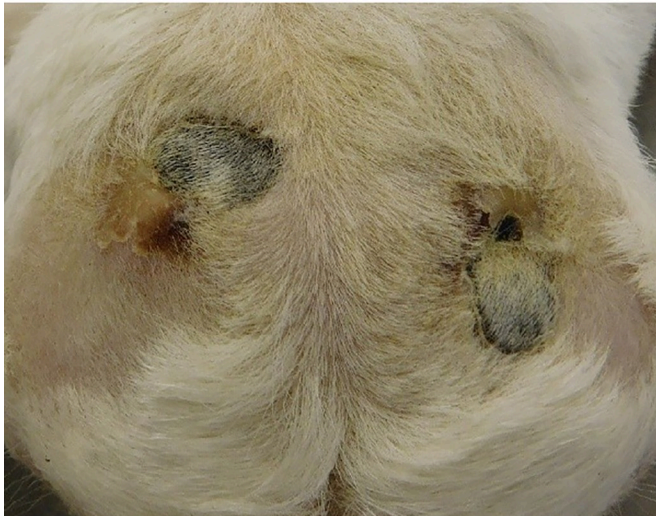This study was conducted on two private commercial dairy goat farms within the Waikato region in New Zealand between June and December 2017. Animals from two farms were required to achieve an adequate sample size of kids (determined by the power analysis). A total of 243 Saanen doe kids (4 ± 1 days old; mean \pm SD) were used (Farm A: 189 kids; Farm B: 54 kids; Saanen was the predominant breed raised on these farms) and were selected for inclusion based on age (2–6 days old) and width of horn buds (< 16 mm). Based on observations from our earlier study, 10-day-old kids with large horn buds grew scurs (i.e. disbudding was unsuccessful [9]); therefore, kids with large horn buds (i.e. > 16 mm) were excluded. The number of kids excluded based on horn bud width was not recorded. Kids had an average body weight of 4.0 ± 0.6 kg (range: 2.7–6.1 kg). Kids were housed in pens (3.5 x 2.0 m) with approximately 15 kids/pen until they were 2 weeks old or were feeding independently, at which point they were moved to larger pens (9.0 x 5.0 m) with approximately 45 kids/pen.

The kids were reared as per routine practice on each farm [22]. The ground within the pens was covered with untreated pine shavings (approximately 10 cm deep). Kids in each pen had *ad libitum* access to milk replacer (SprayFo, AgriVantage, Hamilton, New Zealand; mixed

A



B



C

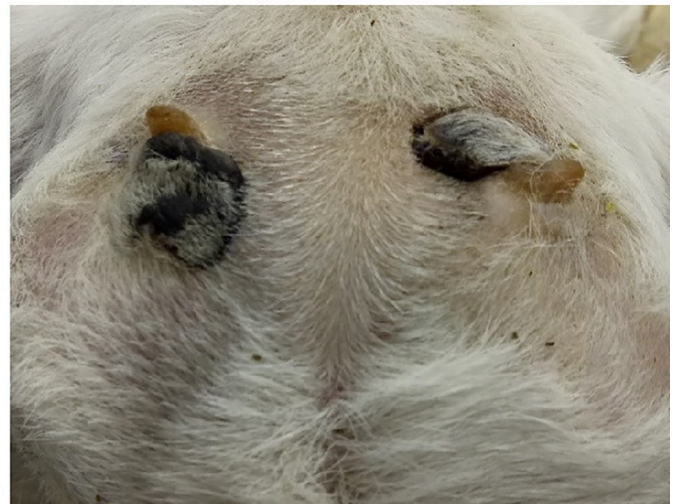
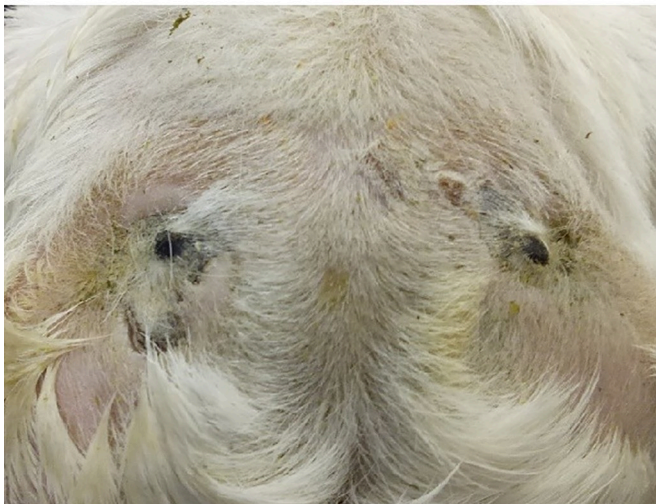
Fig 1. Images of different stages of healing following clove oil injection in dairy goat kids. Images show the dorsal view of the goat kid's head 5 days post-treatment (A), 2 weeks post-treatment (B) and 3 weeks post-treatment (C). Note, that the black scabs covering the horn buds indicate tissue damage and 3 weeks post-treatment, scurs were observed.

<https://doi.org/10.1371/journal.pone.0198229.g001>

according to packet instructions) in feeders (Milk Bar, Waipu, New Zealand) with 10 teats/feeder (36 L capacity) and fresh water in a trough.

Experimental design and treatments

A power analysis for a binary outcome bioequivalence trial was conducted based on 80% power, a 5% significance level and an equivalence range of ± 0.15 . We used a balanced incomplete block design with a different treatment per horn bud, with treatment day, kid, and farm as blocking variables. A replicate consisted of all pairs of treatments and whole replicates were completed per treatment day. Horn buds were randomly allocated treatments ($n = 162$ horn buds/treatment) balanced for kid age and horn bud size (left or right). Kids were given a coloured collar for treatment identification within the pens as they were housed with others not experiencing any treatment. The same veterinary surgeon performed all treatments. The experiment was conducted on 8 treatment days over a 2.5-week period. Kids were fed approximately an hour before treatment and then taken (one at a time) from their home pen and placed in a restraint device (described in Hempstead et al. [10]). Treatments were performed in an alleyway alongside the home pens and treatment order was randomly assigned. Hair covering the horn buds was removed with an electric clipper (Laube, 505 cordless kit, Shoof, Cambridge, New Zealand) to expose the horn buds. Approximately 5 min prior to treatment, kids received an oral non-steroidal anti-inflammatory drug (Loxicom 0.5 mg/mL oral suspension for dogs, Norbrook Laboratories Ltd., Newry, UK; 0.2 mg/kg BW) and a cornual nerve block using lidocaine (Lopaine 2%, 20 mg/mL, Ethical Agents, Auckland, New Zealand; 0.1 mL/horn bud) to reduce pain associated with treatment. The amount of lidocaine used in the present study was less than that used by Alvarez et al. [7] (2 mL/horn bud), who used older animals (10–20 days old vs. 2–6 days old in the present study). Young goat kids have an increased risk of toxicity of lidocaine compared to other ruminants [23, 24] and based on the advice of the veterinary surgeon performing the treatments, a smaller dose was used in the current study.

Treatments included (i) disbudding using a cautery iron ("Quality" electric debudder, 230 V, 190 W; Lister GmbH, Lüdenscheid, Germany), which was heated for 20 min (to reach c. 600°C) prior to being pressed to each horn bud for a total of 5.9 ± 1.1 s (mean \pm SD). Horn buds were then removed by pressing the iron down and rotating so the skin was cut and the buds forcibly flicked out, as described in Hempstead et al. [8] (BUDOFF), (ii) the same procedure as for BUDOFF, except that the horn buds were burnt and the surrounding skin cut but not removed. The iron was held to each horn bud for a total of 4.8 ± 1.1 s on average (BUDON), and (iii) clove oil (C8392, 100mL, 83–85% eugenol, Sigma-Aldrich, Saint Louis, MO) was injected (0.2 mL [21]) laterally into the centre of each horn bud at a 45° angle between the ear and muzzle (20.9 ± 8.4 s; mean completion time \pm SD); details of the procedure are described in Hempstead et al. [9] (CLOVE).

After treatment, BUDON and BUDOFF wounds were sprayed with antibacterial spray (Tetravet, Bayer New Zealand Ltd., Auckland, New Zealand) to prevent infection. Horn buds treated with CLOVE did not receive spray as there were no open wounds. Kids were then returned to their home pen and were monitored for 2 h post-treatment to ensure there were no complications associated with the treatments. The health status and horn bud growth of the goat kids were assessed for 5 months post-treatment as previous observations revealed that no further changes in horn growth occurred past this time. Any kids that died over the course of

the experiment were examined post-mortem by a veterinary surgeon to determine cause of death.

Horn bud growth categories

Horn bud growth categories were defined before the start of the experiment. Each horn bud was categorised based on whether it displayed normal horn growth (H), abnormal growth or scurs (S) or no evidence of growth (N; Fig 2). An extra category was added after the first farm visit 2 weeks after treatment as there were growths that could not be categorised as either H or S—a scorn (SC; Fig 2). A horn was defined as having normal growth without abnormalities. A scur was defined as any abnormal growth with a hardened (keratinised) surface that could be felt by hand in the horn bud area. A scorn was defined as a soft and fibrous growth with a wide base and usually a rounded tip. N was recorded when the skin was smooth and there was no horn growth; this was considered a success. Horn buds were categorised into the four groups fortnightly for 2 months and then monthly for a further 3 months by a trained observer. Intra-observer reliability was measured as the percentage of agreement between an initial and subsequent scoring of 80 images of goat kids showing the three types of horn growth (or no growth); reliability for all four categories was 92%. The observer remained blind to the treatments each kid received. Once growth was observed, that treatment was considered unsuccessful and if both horn buds had evidence of growth, the animal was no longer monitored in subsequent checks. The probability of success, scurs, horns or scorns for each treatment at the final observation are presented.

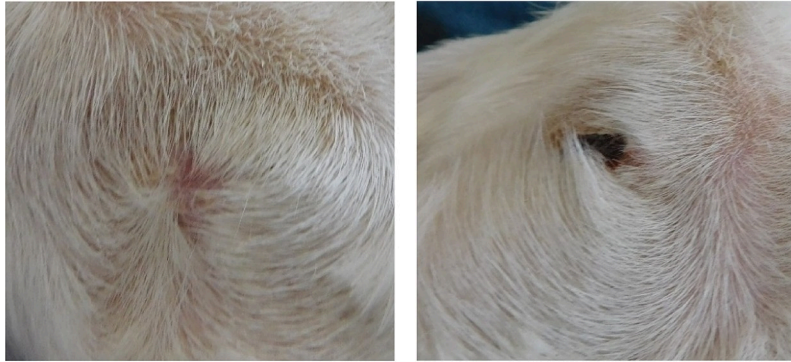
Statistical analysis

Genstat statistical software (version 18, VSN International, Hemel Hempstead, UK) was used to analyse the data. The binary response variables used for analyses included success (no growth = N), scurs (growth = S), horns (growth = H) and scorns (growth = SC); each response variable was assumed to be binomially distributed. Analysis of the differences between treatments were performed independently for all response variables. In addition, a bioequivalence analysis (i.e. test of similarity) was performed for the probability of success, with 80% power and an equivalence range of ± 0.15 . Bioequivalence was assessed for each treatment with BUDOFF (considered the reference treatment) and also for CLOVE and BUDON (with BUDON as the reference treatment). We used a generalised linear mixed model for the analyses with a logit link. The fixed effects were for treatment and the treatment on the other horn bud (i.e. of the same kid). The random effects were for kid, farm, horn bud (left or right) and treatment date within farm. Data presented includes both the bioequivalence and test of a difference between treatments for horn growth. When the denominator degrees of freedom were estimable, *F*-tests were used to assess the statistical significance of the fixed effects. Otherwise, the less reliable chi-square test (i.e. Wald test) was used. Differences between treatment means were compared using Fisher's protected least significant difference test at the 5% significance level.

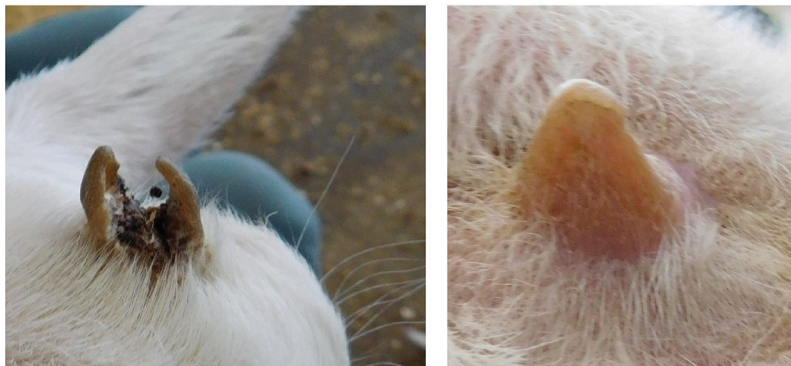Results

Of the 243 kids enrolled in the study, 12 died before their 24 horn buds could be assessed 2 weeks following treatment; one animal (BUDON/BUDOFF) died 2 weeks post-treatment as a result of meningitis below the horn bud but the others died from complications not related to treatment (i.e. pneumonia, digestive issues). Data were missing for 9 BUDON and BUDOFF horn buds and 6 CLOVE horn buds.

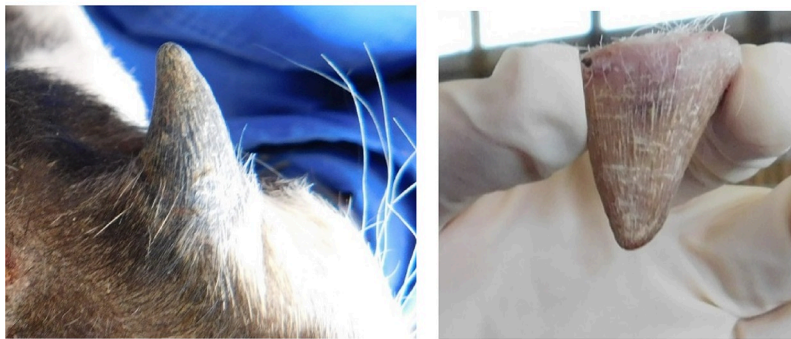
N



S



H



SC

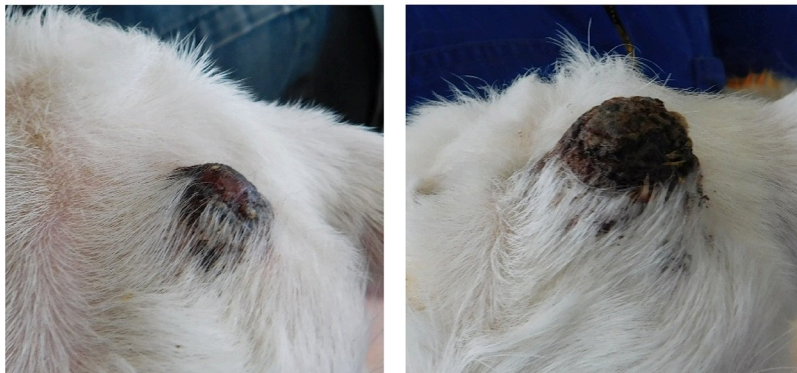

Fig 2. Categories of horn growth in dairy goat kids. No growth = N, scur = S, horn = H and scorn = SC. Goat kids were disbudded using either a clove oil injection (CLOVE), a cauterization iron with the horn buds removed (BUDOFF) or a cauterization iron with the horn buds left intact (BUDON).

<https://doi.org/10.1371/journal.pone.0198229.g002>

There was no evidence of bioequivalence for the probability of success between BUDOFF and CLOVE, nor between BUDOFF and BUDON; however, the probabilities of success for BUDON and CLOVE horn buds were bioequivalent. The differences in the probabilities of success, scurs, horns or scorns are presented in Fig 3. There was an effect of treatment on the probability of success ($F_{2,443} = 43.3, P < 0.001$). The probability of success for BUDOFF horn buds was higher than for BUDON and CLOVE horn buds ($P \leq 0.05$). Furthermore, the probability of success for BUDON horn buds was higher than that of CLOVE horn buds ($P \leq 0.05$).

There was evidence that the treatment on the other horn bud of the same kid, had an effect on the probability of success ($F_{2,375} = 3.9, P = 0.02$). There was a greater probability of success if the other horn bud was treated with BUDOFF (0.42 [0.23, 0.60]) or BUDON (0.31 [0.18, 0.49]; $P \leq 0.05$), but a lower probability of success if the other horn bud was treated with CLOVE (0.21 [0.11, 0.35]); $P \leq 0.05$).

There was a treatment effect on the probability of developing scurs ($F_{2,452} = 28.3, P < 0.001$; Fig 3). The probability of scurs was higher on CLOVE than BUDOFF and BUDON horn buds ($P \leq 0.05$). There was no difference in the probability of scurs for BUDOFF and BUDON horn buds ($P > 0.05$).

There was a treatment effect for the probability of horns ($\chi^2_2 = 8.9, P < 0.001$; Fig 3). The probability of horns was higher for CLOVE than BUDON horn buds ($P \leq 0.05$); horns were not observed for BUDOFF horn buds.

Scorns were only observed for BUDON horn buds (0.41 [0.25, 0.60]). There was an effect of treatment on the probability of horns and scorns combined ($\chi^2_2 = 11.2, P < 0.001$; Fig 3). The probability of scorns and horns was higher for BUDON than CLOVE and BUDOFF horn buds ($P \leq 0.05$).

Discussion

The effectiveness of clove oil injection and two methods of cauterization disbudding (i.e. horn buds removed vs. left intact) in preventing horn growth were evaluated in dairy goat kids. Clove oil injection has been previously reported by Molaei et al., to be 100% successful in preventing horn growth in kids [21] as well as calves [20]. In the present study, the CLOVE treatment appeared to be less effective at preventing horn growth than either of the cauterization disbudding methods based on higher incidence of scurs and horns. The clove oil injection is a novel method of disbudding for goat kids compared with cauterization disbudding (adapted from use in calves), which is the most commonly used method for disbudding goat kids worldwide [1]. Higher proportions of scurs on horn buds treated with clove oil compared with cauterization disbudding may have been associated with difficulties in restricting movement of the head during treatment, although this was not quantified in the present study. Clove oil was applied using a needle injected laterally into the buds, whereas cauterization disbudding involved pressing an ergonomic cauterization iron down on the head. Consistent administration of the full volume of clove oil to the correct location (centre of the horn bud) was not always possible. The injection is likely to cause pain [9] and kids generally struggled (rapid jerks of the head) during the procedure, resulting in the needle becoming dislodged. The creation of an applicator that can quickly deliver a consistent volume of clove oil to the right location may improve efficacy.

Potential explanations for the differences in efficacy of clove oil between Molaei et al. [21] and the present study include differences in methodologies. Molaei et al. [21] used a small

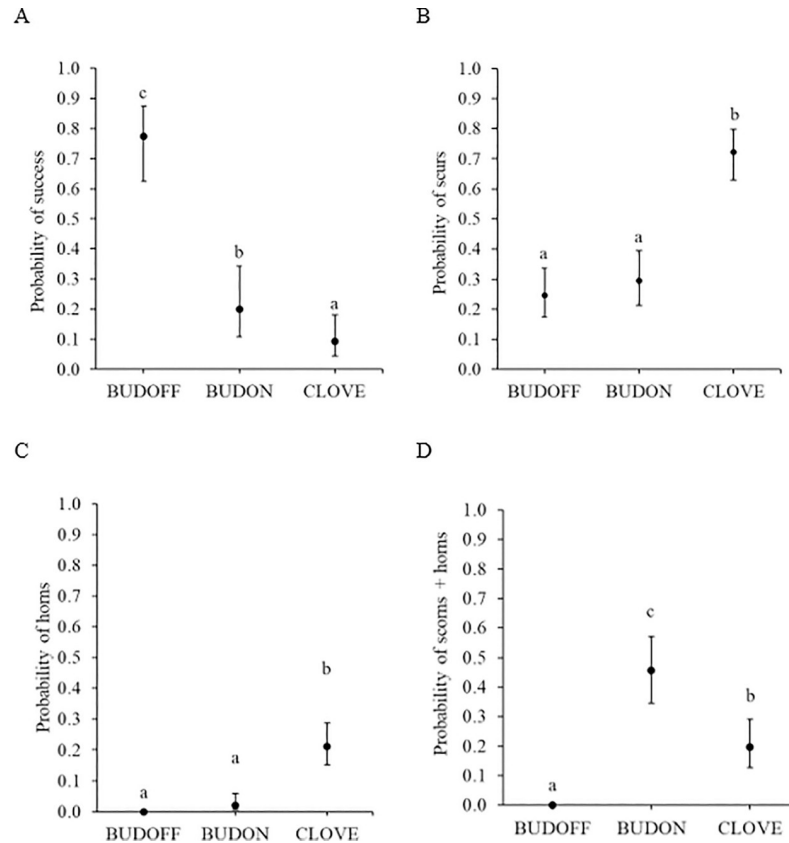


Fig 3. Probability of the four categories of horn growth with 95% confidence intervals for dairy goat kids disbudded using three different techniques. (A) Success (no growth = N), (B) scurs (growth = S), (C) horns (growth = H) and (D) scorns and horn combined (growth = SC or H). Goat kids were disbudded using either clove oil injection (CLOVE; n = 156 horn buds), a cauterization iron with the horn buds removed (BUDOFF; n = 153 horn buds) or a cauterization iron with the horn buds left intact (BUDON; n = 153 horn buds). Means with differing subscripts are significantly different at $P \leq 0.05$.

<https://doi.org/10.1371/journal.pone.0198229.g003>

sample size (16 vs. 243 kids in the present study), and their own clove oil distilled from the spice (clove oil used in the present study was sourced from a commercial manufacturer). The distilled clove oil appeared to be more effective as it totally prevented horn growth in both doe and buck kids, which is notable as horn growth is more precocious in bucks [25]. The exact method of clove oil administration was not completely described in Molaei et al. [21] (e.g., it was not clear how the clove oil was injected or whether the hair was clipped so that any growth could be clearly observed). Perhaps more importantly, Molaei et al. [21] measured horn growth, whereas we evaluated any growth including horns, scurs (of any size) and scorns. It appears as though our methodology for injecting clove oil does not consistently prevent horns or scurs in goat kids and may not be a useful alternative to cauterization disbudding with horn buds removed. Interestingly, there was a similar level of success in preventing scurs or horns between CLOVE and BUDON horn buds, indicating that leaving the horn bud intact may also not prevent horn regrowth. The method used in the present study to evaluate horn bud growth may be more comprehensive than methods used by farmers or farm staff and previous studies [20, 21]. Future research should examine the exact mechanisms of clove oil action on the horn bud tissue of goat kids.

We observed some animals with inflammation of the upper eye lid area below the horn bud associated with the CLOVE treatment (not quantified). This is interesting, as eugenol, the

main component of clove oil, has anti-inflammatory properties [17, 26]. Perhaps blood flow to the horn bud is reduced due to localised cellular necrosis and the observed swelling was pooling of blood below the horn bud. Measures of tissue sensitivity such as pressure algometry [27, 28] or Von Frey filaments [29, 30], could be used to evaluate whether this apparent inflammatory response causes heightened tissue sensitivity.

We also had one kid (treated with BUDOFF and BUDON) die as a result of meningitis, which is likely associated with cautery iron use. It is well-established that cautery iron use can cause damage and thermal injury to the skull and brain, resulting in meningitis [11–13]. Although only one out of 243 kids died as a result of cautery disbudding, this demonstrates the capacity for cautery disbudding to not only cause pain, but mortalities.

To the authors' knowledge, this is the first study to quantify the efficacy of cautery disbudding methods for goat kids. The BUDOFF treatment appeared to be most effective in preventing horns, scurs or scorns compared with the other two methods; this may be due to more complete horn bud destruction as the buds were cauterised and removed. By removing the horn bud, it is easier to ensure that all of the horn bud tissue is destroyed. It is generally considered more efficacious to remove the horn buds than leaving them on [1] and this method has been favoured in other studies [7, 30, 31]. However, removing the horn bud results in large open wounds [9], increasing the risk of bacterial infection, which can have negative welfare implications.

The BUDON method resulted in abnormal growths that were soft, fibrous and fitted into neither the horn nor scur categories. The cautery iron used in the present study had a hollow centre with hot edges that cut into the skin, which may have allowed for the inner cells of the horn bud to continue to grow. This result has implications for farmers and contractors as it suggests that removing the horn buds may be more effective for preventing scurs than burning alone.

Some studies, that have conducted welfare assessments of commercial dairy goats, have used the number of adult female goats with scurs as a measure of improper disbudding in England, Portugal and Italy [32–34]. These studies reported that 6.4%, 10.8% and 12.7% (respectively) of goats assessed had scurs; however, the method of disbudding used on these dairy goats was not described and only adult goats were observed. Further research on scur or horn growth rates in goat kids after disbudding could help quantify the efficacy of cautery disbudding methods.

In order to understand regrowth associated with disbudding, it is important to understand how horns grow. The process involves keratinisation of the horn bud epidermis and ossification of the underlying dermis and hypodermis [35]. Goat horn anatomy is similar to that of cattle horns; the horn comprises tightly packed tubules produced by corium and germinal epithelium, which is attached to the frontal bone. The cornual diverticulum of the frontal sinus forms a cavity within the horn [1]. If the horn bud epidermis is not completely destroyed then keratinisation of some epidermal cells can occur resulting in scurs. Scurs usually result from inadequate burning of the horn bud site in an effort to reduce the risk of thermal injury to the skull and brain [25] or insufficient removal of the germinal tissue from the base of the horn bud [15]. If the base of the horn bud, which can be difficult to see, is wider than the diameter of the cautery iron and not all tissue is destroyed, then scurs may also develop. In the present study, kids were selected for inclusion based on horn bud width; therefore, the width of the horn bud (i.e. < 16 mm) may have been too large for adequate cell destruction to occur. In future studies, kids with smaller or less developed horn buds should be assessed. Interestingly, in many cattle breeds, there is a gene for scurs [36–38], as well as polled and horned genes [39], meaning that scurs can grow naturally without disbudding. It is unknown whether a gene

for scurs exists in goats. If so, herds with high rates of scurs may be associated with the genetic potential to grow scurs.

Interestingly, there appeared to be a reduced rate of efficacy if one of the horn buds on an individual kid was injected with clove oil. In addition, cauterly disbudding of one horn bud showed a greater rate of success on the other horn bud. We had not anticipated either clove oil or the cauterly iron to affect the efficacy of the treatment on the other horn bud, and the incomplete block design was chosen to minimize animal numbers and control for variability within kids. However, the experiment was not designed to assess interactions between treatments on the same kid; therefore, the result could be spurious. Future researchers should consider using only one disbudding method per animal. Unfortunately, this would increase the number of animals required.

A useful alternative to reduce pain and complications associated with cauterly disbudding, would be to breed polled goats to eliminate the need for this procedure. There are hurdles to achieving this however, as the gene for polledness is linked with the intersex gene in goats [40]. This means that there is a high probability that naturally polled goats will be infertile. In addition, pain and injuries associated with disbudding can be eliminated if disbudding was not performed and farm management and facilities allowed for goats with horns. Until either a polled line can be established, or management of horned goats is fully assessed, mitigating pain associated with cauterly disbudding or evaluating new alternatives that cause less pain or injury than cauterly disbudding should be considered.

Conclusions

Clove oil injection did not appear to be as successful at preventing scurs or horns as cauterly disbudding and therefore the methodology used in this study may not be useful for disbudding goat kids. Interestingly, cauterly disbudding by removing the horn bud germinal tissue was more efficacious than leaving the horn buds intact, suggesting that the former method may be more effective for preventing horns, scurs or scorns. Future research should explore other alternatives to cauterly disbudding that may be efficacious and cause less pain.

Supporting information

S1 Dataset. Dataset of horn growth of goat kids disbudded using three different techniques. Goat kids were disbudded with either clove oil injection (CLOVE), a cauterly iron with the horn buds removed (BUDOFF) or a cauterly iron with the horn buds left intact (BUDON). (XLSX)

Acknowledgments

We are grateful for assistance provided by AgResearch staff and students especially Ashleigh Weatherall, Rose Greenfield, Kirsty Owens, Rosalie Carter, Bridget Wise, Frances Huddart, Ariane Bright, Trevor Watson, Stephanie Delaney, Remi Mathieu, Gemma Lowe, Suzanne Dowling, Laura Hunter, Ben Ferniot and Johan Larive. We also thank Ali Cullum for her many contributions to this study and performing the disbudding treatments and the participating DGC farmers and farm staff. We also acknowledge assistance from Alan Julian for carrying out the pathology work. We are grateful to Cheryl O'Connor and Vicki Burggraaf for reviewing this paper.

Author Contributions

Conceptualization: Melissa N. Hempstead, Joseph R. Waas, Mairi Stewart, Mhairi A. Sutherland.

Data curation: Melissa N. Hempstead, Vanessa M. Cave.

Formal analysis: Melissa N. Hempstead, Vanessa M. Cave.

Funding acquisition: Mairi Stewart, Mhairi A. Sutherland.

Investigation: Melissa N. Hempstead.

Methodology: Melissa N. Hempstead, Joseph R. Waas, Mairi Stewart, Vanessa M. Cave, Mhairi A. Sutherland.

Project administration: Melissa N. Hempstead, Amanda R. Turner.

Resources: Melissa N. Hempstead, Amanda R. Turner, Mhairi A. Sutherland.

Software: Vanessa M. Cave.

Supervision: Joseph R. Waas, Mairi Stewart, Mhairi A. Sutherland.

Writing – original draft: Melissa N. Hempstead.

Writing – review & editing: Melissa N. Hempstead, Joseph R. Waas, Mairi Stewart, Vanessa M. Cave, Amanda R. Turner, Mhairi A. Sutherland.

References

1. Smith MC, Sherman DM. Dehorning and descanting. In: Smith MC, Sherman DM, editors. *Goat Medicine*. 2nd ed. New Jersey: Wiley-Blackwell; 2009. p. 723–31.
2. Waiblinger S, Schmied-Wagner C, Mersmann D, Nordmann E. Social behaviour and injuries in horned and hornless dairy goats. In: Kofer J, Schobesberger H, editors. *Proceedings of the XVth International Congress of the International Society for Animal Hygiene*; 2011 Jul 3–7; Vienna, Austria. Czech Republic: Tribun EU; 2011. p. 421–2.
3. Loretz C, Wechsler B, Hauser R, Rusch P. A comparison of space requirements of horned and hornless goats at the feed barrier and in the lying area. *Appl. Anim. Behav. Sci.* 2004; 87(3–4):275–83.
4. Graf B, Senn M. Behavioural and physiological responses of calves to dehorning by heat cauterization with or without local anaesthesia. *Appl. Anim. Behav. Sci.* 1999; 62(2–3):153–71.
5. Stafford KJ, Mellor DJ. Dehorning and disbudding distress and its alleviation in calves. *Vet. J.* 2005; 169(3):337–49. <https://doi.org/10.1016/j.tvjl.2004.02.005> PMID: 15848777
6. Sylvester SP, Stafford KJ, Mellor DJ, Bruce RA, Ward RN. Behavioural responses of calves to amputation dehorning with and without local anaesthesia. *Aust. Vet. J.* 2004; 82(11):697–700. PMID: 15977616
7. Alvarez L, De Luna JB, Gamboa D, Reyes M, Sánchez A, Terrazas A, et al. Cortisol and pain-related behavior in disbudded goat kids with and without cornual nerve block. *Physiol. Behav.* 2015; 138:58–61. <https://doi.org/10.1016/j.physbeh.2014.10.026> PMID: 25447328
8. Hempstead MN, Waas JR, Stewart M, Cave VM, Sutherland MA. Behavioural response of dairy goat kids to cautery disbudding. *Appl. Anim. Behav. Sci.* 2017; 194:42–7.
9. Hempstead MN, Waas JR, Stewart M, Cave VM, Sutherland MA. Evaluation of alternatives to cautery disbudding of dairy goat kids using physiological measures of immediate and longer-term pain. *J. Dairy Sci.* 2018; 101(6):5374–87. <https://doi.org/10.3168/jds.2017-13814> PMID: 29573796
10. Hempstead MN, Waas JR, Stewart M, Dowling SK, Cave VM, Lowe GL, et al. Effect of isoflurane alone or in combination with meloxicam on the behavior and physiology of goat kids following cautery disbudding. *J. Dairy Sci.* 2018; 101(4):3193–204. <https://doi.org/10.3168/jds.2017-13507> PMID: 29397164
11. Sanford SE. Meningoencephalitis caused by thermal disbudding in goat kids. *Can. Vet. J.* 1989; 30(10):832.
12. Thompson KG, Bateman RS, Morris PJ. Cerebral infarction and meningoencephalitis following hot-iron disbudding of goat kids. *N. Z. Vet. J.* 2005; 53(5):368–70. <https://doi.org/10.1080/00480169.2005.36578> PMID: 16220135

13. Wright HJ, Adams DS, Trigo FJ. Meningoencephalitis after hot-iron disbudding of goat kids. *Vet. Med. Small Anim. Clin.* 1983; 78(4):599–601.
14. Hague BA, Neil Hooper R. Cosmetic dehorning in goats. *Vet. Surg.* 1997; 26(4):332–4. PMID: [9232792](https://pubmed.ncbi.nlm.nih.gov/9232792/)
15. Hartnack AK, Jordan ME, Roussel AJ. Complications associated with surgical dehorning in goats: A retrospective study of 239 cases. *Vet. Surg.* 2018; 47(2):188–92. <https://doi.org/10.1111/vsu.12743> PMID: [29239476](https://pubmed.ncbi.nlm.nih.gov/29239476/)
16. Hempstead MN, Waas JR, Stewart M, Cave VM, Sutherland MA. Evaluation of alternatives to cauterly disbudding of dairy goat kids using behavioural measures of post-treatment pain. *Appl. Anim. Behav. Sci.* 2018; 206:32–8.
17. Markowitz K, Moynihan M, Liu M, Kim S. Biologic properties of eugenol and zinc oxide-eugenol: A clinically oriented review. *Oral Surg. Oral Med. Oral Pathol.* 1992; 73(6):729–37. PMID: [1437045](https://pubmed.ncbi.nlm.nih.gov/1437045/)
18. Kozam G, Mantell GM. The effect of eugenol on oral mucous membranes. *J. Dent. Res.* 1978; 57(11–12):954–7. <https://doi.org/10.1177/00220345780570110901> PMID: [281340](https://pubmed.ncbi.nlm.nih.gov/281340/)
19. Prashar A, Locke IC, Evans CS. Cytotoxicity of clove (*Syzygium aromaticum*) oil and its major components to human skin cells. *Cell Prolif.* 2006; 39(4):241–8. <https://doi.org/10.1111/j.1365-2184.2006.00384.x> PMID: [16872360](https://pubmed.ncbi.nlm.nih.gov/16872360/)
20. Molaei MM, Azari O, Esmailzadeh S. Study of calves disbudding following injection of clove oil under horn bud. *J. Vet. Res.* 2014; 69(4):363–9.
21. Molaei MM, Mostafavi A, Kheirandish R, Azari O, Shaddel M. Study of disbudding goat kids following injection of clove oil essence in horn bud region. *Vet. Res. Forum.* 2015; 6(1):17–22. PMID: [25992247](https://pubmed.ncbi.nlm.nih.gov/25992247/)
22. Dairy Goat Co-Operative. Code of Farm Practice. Dairy Goat Co-Operative NZ Ltd.; 2012.
23. Smith MC, Sherman DM. Anesthesia. In: Smith MC, Sherman DM, editors. *Goat Medicine*. 2nd ed. New Jersey: Wiley-Blackwell; 2009. p. 710–20.
24. Dugdale A. *Veterinary Anaesthesia: Principles to Practice*. 1st ed. New Jersey: Wiley-Blackwell. 2011.
25. Dawson L, Allen J, Olcott B. Meat goat herd health procedures and prevention. In: Sahlu T, editor. *Proceedings of the 22nd Annual Goat Field Day*; Langston: Langston University; 2007. p. 18–44.
26. Daniel AN, Sartoretto SM, Schmidt G, Caparroz-Assef SM, Bersani-Amado CA, Cuman RKN. Anti-inflammatory and antinociceptive activities of eugenol essential oil in experimental animal models. *Rev. bras. Farmacogn.* 2009; 19(1B):212–7.
27. Heinrich A, Duffield TF, Lissemore KD, Millman ST. The effect of meloxicam on behavior and pain sensitivity of dairy calves following cauterly dehorning with a local anesthetic. *J. Dairy Sci.* 2010; 93(6):2450–7. <https://doi.org/10.3168/jds.2009-2813> PMID: [20494153](https://pubmed.ncbi.nlm.nih.gov/20494153/)
28. Allen KA, Coetzee JF, Edwards-Callaway LN, Glynn H, Dockweiler J, KuKanich B, et al. The effect of timing of oral meloxicam administration on physiological responses in calves after cauterly dehorning with local anesthesia. *J. Dairy Sci.* 2013; 96(8):5194–205. <https://doi.org/10.3168/jds.2012-6251> PMID: [23746590](https://pubmed.ncbi.nlm.nih.gov/23746590/)
29. Espinoza C, Lomax S, Windsor P. The effect of a topical anesthetic on the sensitivity of calf dehorning wounds. *J. Dairy Sci.* 2013; 96(5):2894–902. <https://doi.org/10.3168/jds.2012-5954> PMID: [23477817](https://pubmed.ncbi.nlm.nih.gov/23477817/)
30. Mintline EM, Stewart M, Rogers AR, Cox NR, Verkerk GA, Stookey JM, et al. Play behavior as an indicator of animal welfare: Disbudding in dairy calves. *Appl. Anim. Behav. Sci.* 2013; 144(1–2):22–30.
31. Huebner KL, Kunkel AK, McConnel CS, Callan RJ, Dinsmore RP, Caixeta LS. Evaluation of horn bud wound healing following cauterly disbudding of preweaned dairy calves treated with aluminum-based aerosol bandage. *J. Dairy Sci.* 2017; 100(5):3922–9. <https://doi.org/10.3168/jds.2016-12192> PMID: [28259415](https://pubmed.ncbi.nlm.nih.gov/28259415/)
32. Anzuino K, Bell NJ, Bazeley KJ, Nicol CJ. Assessment of welfare on 24 commercial UK dairy goat farms based on direct observations. *Vet. Rec.* 2010; 167(20):774–80. <https://doi.org/10.1136/vr.c5892> PMID: [21262609](https://pubmed.ncbi.nlm.nih.gov/21262609/)
33. Battini M, Barbieri S, Vieira A, Stilwell G, Mattiello S. Results of testing the prototype of the AWIN welfare assessment protocol for dairy goats in 30 intensive farms in Northern Italy. *Ital. J. Anim. Sci.* 2016; 15(2):283–93.
34. Can E, Vieira A, Battini M, Mattiello S, Stilwell G. On-farm welfare assessment of dairy goat farms using animal-based indicators: The example of 30 commercial farms in Portugal. *Acta Agric. Scand.* 2016; 66(1):43–55.
35. Dove WF. The physiology of horn growth: A study of the morphogenesis, the interaction of tissues, and the evolutionary processes of a mendelian recessive character by means of transplantation of tissues. *J. Exp. Zool.* 1935; 69(3):347–405.

36. Capitan A, Grohs C, Weiss B, Rossignol MN, Reversé P, Eggen A. A newly described bovine type 2 scurs syndrome segregates with a Frame-Shift mutation in TWIST1. *PLoS ONE*. 2011; 6(7).
37. Mariasegaram M, Reverter A, Barris W, Lehnert SA, Dalrymple B, Prayaga K. Transcription profiling provides insights into gene pathways involved in horn and scurs development in cattle. *BMC Genomics*. 2010; 11(1):370.
38. Ward J. Understanding horned/polled and scurred traits. *Hereford World*. 2015. Available from https://hereford.org/static/files/1115_PerformanceMatters.pdf
39. Prayaga KC. Genetic options to replace dehorning in beef cattle—A review. *Aust. J. Agric. Res.* 2007; 58(1):1–8.
40. Pailhoux E, Vigier B, Chaffaux S, Serval N, Taourit S, Furet JP, et al. A 11.7-kb deletion triggers intersexuality and polledness in goats. *Nat. Genet.* 2001; 29(4):453–8. <https://doi.org/10.1038/ng769> PMID: 11726932