

RESEARCH ARTICLE

# Comparison of diagnostic accuracy of magnetic resonance elastography and Fibroscan for detecting liver fibrosis in chronic hepatitis B patients: A systematic review and meta-analysis

Huanming Xiao<sup>1</sup>, Meijie Shi<sup>1,2</sup>, Yubao Xie<sup>1</sup>, Xiaoling Chi<sup>1\*</sup>

**1** Hepatology Department, Guangdong provincial hospital of Chinese Medicine, The Second Affiliated Hospital of Guangzhou University of Chinese Medicine, Guangzhou, Guangdong, China, **2** Guangzhou University of Chinese Medicine, Guangzhou, Guangdong, China

\* [chixiaolingqh@163.com](mailto:chixiaolingqh@163.com)



**OPEN ACCESS**

**Citation:** Xiao H, Shi M, Xie Y, Chi X (2017) Comparison of diagnostic accuracy of magnetic resonance elastography and Fibroscan for detecting liver fibrosis in chronic hepatitis B patients: A systematic review and meta-analysis. PLoS ONE 12(11): e0186660. <https://doi.org/10.1371/journal.pone.0186660>

**Editor:** Ferruccio Bonino, Università degli Studi di Pisa, ITALY

**Received:** June 8, 2017

**Accepted:** October 5, 2017

**Published:** November 6, 2017

**Copyright:** © 2017 Xiao et al. This is an open access article distributed under the terms of the [Creative Commons Attribution License](https://creativecommons.org/licenses/by/4.0/), which permits unrestricted use, distribution, and reproduction in any medium, provided the original author and source are credited.

**Data Availability Statement:** All relevant data are within the paper and its Supporting Information files.

**Funding:** This study was supported by grant number: 2013ZX10005002-002, URL: <http://www.nmp.gov.cn/>. XLC received the funding. The funders had no role in study design, data collection and analysis, decision to publish, or preparation of the manuscript.

## Abstract

### Aim

This systematic review and meta-analysis was carried out to compare the diagnostic accuracy of Magnetic resonance elastography (MRE) and Fibroscan for detecting liver fibrosis in Chronic Hepatitis B (CHB) patients.

### Methods

The PubMed, the Cochrane Library, and the Web of science databases were searched for studies that evaluated the diagnostic value of MRE and Fibroscan for liver fibrosis in CHB patients until March 1<sup>st</sup> 2017. The quality of the included studies was assessed by the revised Quality Assessment for Studies of Diagnostic Accuracy tool (QUADAS-2). Meta-disc 4.1 was used to summary the area under receiver operating characteristics curve (AUROC), sensitivity, specificity, diagnostic odds ratios to assess the accuracy of staging liver fibrosis using MRE and Fibroscan.

### Results

A total of nine MRE studies with 1470 patients and fifteen Fibroscan studies with 3641 patients were included in this systematic review. The summary AUROC values using MRE and Fibroscan for detecting significant fibrosis, advanced fibrosis and cirrhosis were 0.981 vs. 0.796 ( $p < 0.001$ ), 0.972 vs. 0.893 ( $p < 0.001$ ), and 0.972 vs. 0.905 ( $p < 0.001$ ). The pooled sensitivity and specificity using MRE for the diagnosis of significant fibrosis, advanced fibrosis and cirrhosis were 92.8% and 93.7%, 89.6% and 93.2%, 89.5% and 92.0%, respectively. The pooled sensitivity and specificity using Fibroscan for the diagnosis of significant fibrosis, advanced fibrosis and cirrhosis were 71.6% and 81.6%, 79.0% and 84.6%, 80.0% and 86.6%, respectively.

**Competing interests:** The authors have declared that no competing interests exist.

## Conclusion

MRE is more accurate than Fibroscan in diagnosing liver fibrosis in CHB patients, especially in diagnosing significant fibrosis and advanced fibrosis.

## Introduction

Liver fibrosis is a vital wound-healing response during the process of progression from chronic hepatitis B (CHB) to cirrhosis[1]. It can be found in most of the CHB patients. Liver fibrosis progression can lead to cirrhosis, even result in long term sequelae, such as portal hypertension, liver failure, hepatocellular carcinoma and so on[1]. It is also considered to be the main cause of hepatitis B associated morbidity and mortality[2]. Hence, diagnosis of liver fibrosis plays an important role during the process of making therapeutic decisions as well as predicting disease outcomes, or following up of liver fibrosis progression in CHB patients.

Although liver biopsy has long been considered the “gold standard” for determine the stages of liver fibrosis, it cannot be widely used in clinical practice for its limitations and risks, such as sample errors, poor tolerance, high cost and risk of hemorrhage, etc. Therefore, an increasing number of investigations have focused on the noninvasive methods in order to more accurately identify patients with different stages of fibrosis[3–5]. Fibroscan (Transient Elastography) is one of such safer and more acceptable noninvasive models, which has been used widely in China and also been recommended by World Health Organization in clinical application[6]. Magnetic Resonance Elastography (MRE) is a new elastography method, which has been developed to improve the accuracy of diagnostic of liver fibrosis. However, the accuracy of MRE and Fibroscan is still controversial. Some researchers found that MRE has higher diagnostic accuracy than Fibroscan for staging liver fibrosis[7], while other researchers revealed that the accuracy of staging liver fibrosis is comparable between MRE and Fibroscan [8]. Therefore, the present meta-analysis aims to compare the diagnosis accuracy of MRE and Fibroscan for detecting liver fibrosis in CHB patients.

## Materials and methods

### Search strategy

The PubMed, the Cochrane Library, and the Web of Science databases were searched for studies, which evaluated the diagnostic value of MRE and Fibroscan for liver fibrosis in CHB patients until March 1<sup>st</sup> 2017. The search terms included Magnetic resonance elastography, MR Elastography, Fibroscan, Transient elastography, liver biopsy, chronic hepatitis B, noninvasive models and liver fibrosis. The inclusion criteria of included studies was as follows: (1) the study evaluated the accuracy of MRE or Fibroscan for diagnosis liver fibrosis in CHB patients; (2) the study used liver biopsy as the reference standard for staging liver fibrosis; (3) the study reported sensitivity, specificity and the number of patients in different fibrosis stage which could be extracted to get the data of true positive, false positive, true negative and false negative; (4) the study enrolled more than 50 patients and (5) the studies should be published in international journals cited by SCI and the language should be in English. The studies with any of the following conditions were excluded: (1) studies were not relevant to MRE or Fibroscan diagnosis; (2) manuscripts have only abstracts, or correspondence letter, or author comments (3) animal studies or studies on children; (4) data incomplete or no liver biopsy or small sample size.

## Data extraction

Two reviewers extracted the required information of the included studies independently. The required data elements included author, region, the year of article publication, study design, patients' age, sex, and liver biopsy scoring system, liver biopsy size, interval time between biopsy and MRE or Fibroscan as well as the sensitivity, specificity and the number of patients in different fibrosis stage. The quality of the studies included in this review was assessed by the revised Quality Assessment for Studies of Diagnostic Accuracy tool (QUADAS-2)[9]. Significant fibrosis, advanced fibrosis and cirrhosis was defined as stages of F2-F4, F3-F4 and F4 by Metavir score[10] or Batts and Ludwig score[11]. Liver stiffness assessed by Fibroscan is quantitatively analyzed for liver fibrosis and expressed as kilopascals (kPa).

## Data synthesis and analysis

Statistical analysis was performed by Meta-Disc software 1.4, Review Manager 5.3 and stata10.0. The data was extracted and the fourfold table was constructed to calculate the sensitivity, specificity, positive and negative likelihood ratio and diagnostic odds ratio (DOR). Area under the summary receiver operating characteristic (AUROC) curves and the cut-off were recalculated to compare the accuracy of MRE and Fibroscan for the diagnosis of significant fibrosis, advanced fibrosis and cirrhosis. A diagnostic tool is defined as perfect if AUC is 1.00, excellent if the AUC is greater than 0.90, good if it is greater than 0.80, moderate if it is less than 0.80[12]. The Z test was used to compare the summary AUROC values of these two non-invasive models for predicting liver fibrosis. The summary DORs, the summary sensitivity and specificity were also calculated to further examine the accuracy of MRE and Fibroscan for liver fibrosis.

## Assessment of heterogeneity and publication bias

The following methods have been used to evaluate the heterogeneity in our meta-analysis. The spearman's correlation between the logit of sensitivity and 1-specificity was calculated to evaluate the threshold heterogeneity of the included studies. If  $P < 0.05$ , it suggests that the threshold heterogeneity was observed. The Cochrane-Q test was used to assess the non-threshold heterogeneity of included studies. The inconsistency index  $I^2$  was calculated to qualify the amount of non-threshold heterogeneity. If the inconsistency index  $I^2 \geq 30\%$ ,  $\geq 50\%$  or  $\geq 75\%$  was considered as moderate, substantial or considerable heterogeneity, respectively. Possible publication bias was assessed by a linear regression test of funnel plot asymmetry using a Deeks plot.

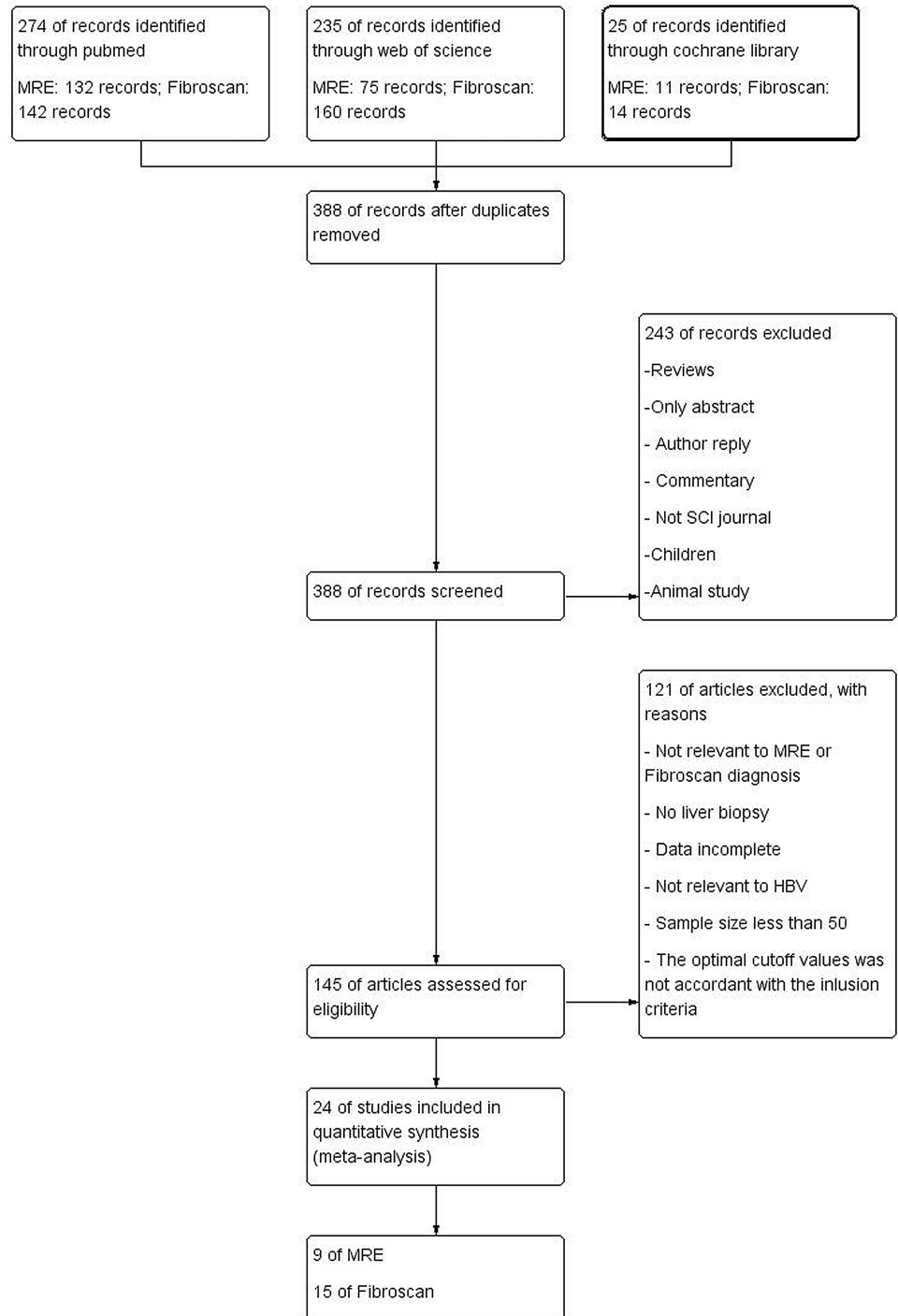
## Results

### Search results

388 studies were initially screened after removal of 146 duplicates. However, 363 studies were excluded for some reasons, such as only abstract, not relevant to MRE or Fibroscan diagnosis, animal study, or data incomplete, etc. Finally, 24 studies including 5111 patients were included for evaluation and meta-analysis[4, 7, 13–34]. The study flow diagram is shown in Fig 1.

### Basic characteristics of the included studies

Nine MRE studies including 1470 patients (mean age: 52.9 years; 65.0% male) and fifteen Fibroscan studies including 3641 patients (mean age: 40.8 years; 72.3% male) were systematic reviewed. Twenty two studies used the Metavir score and two studies used the Batts and



**Fig 1. The study flow diagram.** Published studies were identified to assess the accuracy of MRE and Fibrosan for diagnosing liver fibrosis.

<https://doi.org/10.1371/journal.pone.0186660.g001>

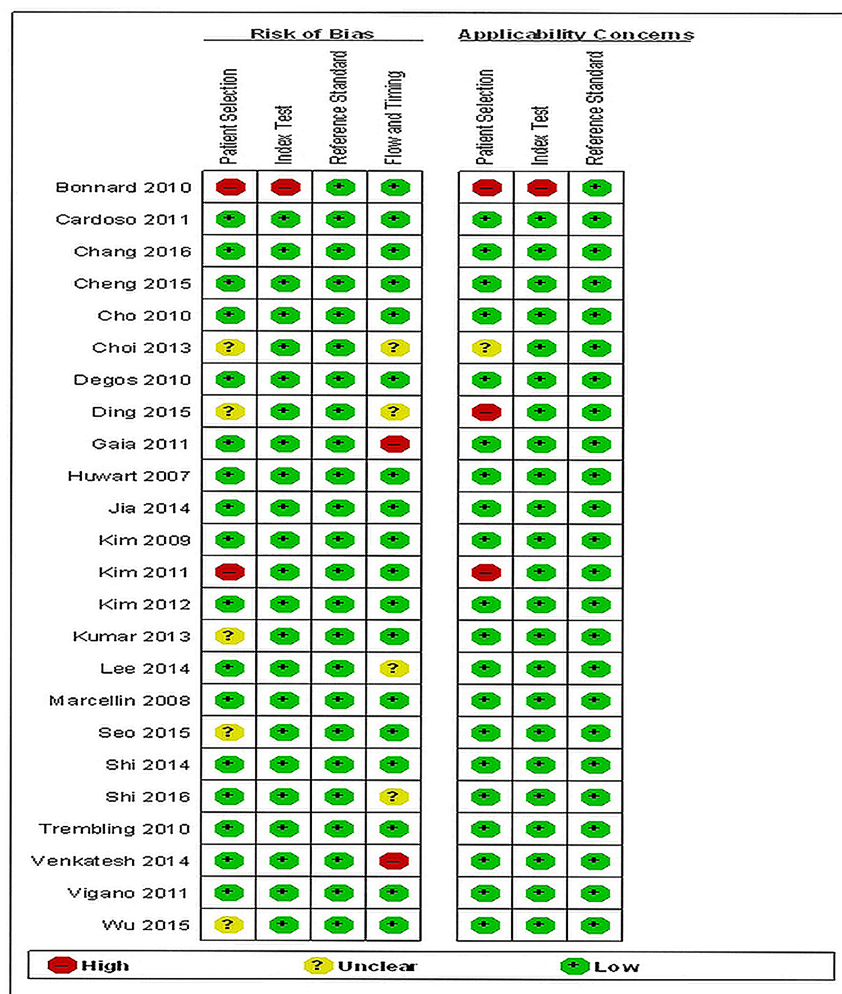
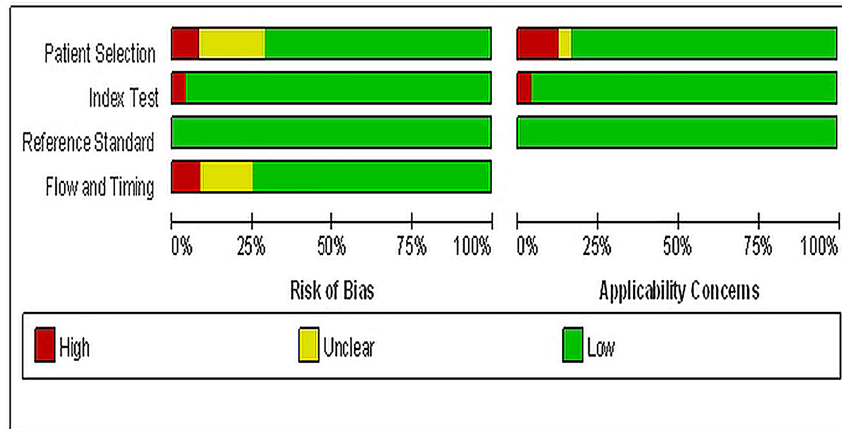
Ludwig score to assess the stages of liver fibrosis. Five of Nine MRE studies and thirteen of fourteen Fibrosan studies were prospective studies. More detailed characteristics of the enrolled studies were listed in Table 1, while Methodological quality of included studies according to QUADAS-2 was shown in Fig 2.



**Table 1. Characteristics of the included studies.**

Models	Author, Year, Region	Study/center Description	N	Interval between biopsy and MRE or Fibroscan	Median/ MeanAge (Years)Males (%)	Liver biopsy scoring system	Liver Biopsy length (mm)	For diagnosis stages of liver fibrosis
Fibroscan	Bonnard, 2010, France	Prospective One center	59	<6 months	35(68)	METAVIR	Unclear	F2, F4
Fibroscan	Cardoso, 2012, France	Prospective One center	202	Same day	41(80)	METAVIR	19±6	F2, F3,F4
Fibroscan	Cheng, 2015, China	Prospective Seven centers	459	Same day	33(74)	METAVIR	>10	F2, F3
Fibroscan	Cho, 2011, Korea	Prospective One center	121	Same day	39(67)	Batts and Ludwig	>15	F2, F3
Fibroscan	Gaia, 2011, Italy	Prospective One center	70	<6 months	44(71)	METAVIR	>20	F2, F3
Fibroscan	Jia, 2015, China	Prospective Seven centers	469	<6 months	34(74)	METAVIR	>10	F2, F3
Fibroscan	Kim, 2012, Korea	Prospective One center	194	Same day	47(61)	Batts and Ludwig	>20	F2, F3,F4
Fibroscan	Marcellin, 2009, France	Prospective Five centers	173	<3 months	40(67)	METAVIR	16±6	F2, F3,F4
Fibroscan	Seo, 2015, Korea	Prospective Fifty-five centers	567	<3 months	45(67)	METAVIR	>15	F2, F3,F4
Fibroscan	Degos, 2010, France	Prospective twenty-three centers	284	<1 month	38(81)	METAVIR	24	F4
Fibroscan	Ding, 2015, China	Retrospective One center	406	Unclear	42(73)	METAVIR	unclear	F4
Fibroscan	Kumar, 2013, India	Prospective One center	200	<1 week	38(80)	METAVIR	>15	F4
Fibroscan	Trembling, 2014, Italy	Prospective One center	182	Same day	46(71)	METAVIR	>20	F3, F4
Fibroscan	Vigano, 2011, Italy	Prospective One center	125	Same day	47(71)	METAVIR	>20	F4
Fibroscan	Kim, 2009, Korea	Prospective One center	130	Same day	43(79)	METAVIR	Unclear	F4
MRE	Chang, 2016, Korea	Retrospective One center	281	<3 months	56(57)	METAVIR	>20	F2, F3,F4
MRE	Choi, 2013, Korea	Retrospective One center	173	Unclear	57(75)	METAVIR	Unclear	F2, F3,F4
MRE	Huwart, 2008, Belgium	Prospective One center	88	2 days	54(42)	METAVIR	34±10	F2, F3,F4
MRE	Kim, 2011, Korea	Prospective One center	60	<58 days	58(84)	METAVIR	Unclear	F2, F3,F4
MRE	Lee, 2014, Korea	Retrospective One center	334	Unclear	56(81)	METAVIR	Unclear	F2, F3,F4
MRE	Shi, 2014, China	Prospective One center	113	23 days	42 (43)	METAVIR	14±7	F2, F3,F4
MRE	Shi, 2016, China	Prospective One center	173	Unclear	43(60)	METAVIR	>15	F2, F3,F4
MRE	Venkatesh, 2014, Singapore	Prospective One center	63	<6 months	50(70)	METAVIR	Unclear	F2, F3,F4
MRE	Wu, 2015, Taiwan	Retrospective One center	185	Unclear	59(75)	METAVIR	>10	F2, F3,F4

<https://doi.org/10.1371/journal.pone.0186660.t001>



**Fig 2. Methodological quality of included studies according to the revised quality assessment for studies of diagnostic accuracy tool (QUADAS-2) (+: yes; -: no; unclear).**

<https://doi.org/10.1371/journal.pone.0186660.g002>

**Table 2. Meta-analysis results of MRE and Fibroscan for prediction of significant fibrosis, advanced fibrosis and cirrhosis.**

	Number of Studies (Patients)	Cutoff value (Mean, Range) (kPa)	Summary Sensitivity (95% CI, %)	Summary Specificity (95% CI, %)	Summary LR+ (95%CI)	Summary LR- (95%CI)	Summary AUROC	Summary DOR(95%CI)
<b>Significant fibrosis</b>								
<b>MRE</b>	9 (2314)	2.99 (2.5–4.69)	92.8 (91.0–94.4)	93.7 (91.3–95.6)	14.27 (8.14–25.01)	0.07 (0.05–0.11)	0.981	234.15 (116.40–471.04)
<b>Fibroscan</b>	9 (1470)	7.53 (7.2–8.5)	71.6 (69.1–74.0)	81.6 (78.9–84.2)	3.83 (3.11–4.73)	0.35 (0.31–0.39)	0.796	11.07 (8.14–15.07)
<b>Advanced fibrosis</b>								
<b>MRE</b>	9 (1470)	3.62 (2.92–5.45)	89.6 (87.1–91.7)	93.2 (91.1–94.9)	10.87 (7.92–14.89)	0.09 (0.06–0.16)	0.972	137.57 (61.33–308.55)
<b>Fibroscan</b>	9 (2437)	9.15 (8.1–10.5)	79.0 (76.1–81.6)	84.6 (82.7–86.3)	5.23 (4.02–6.79)	0.25 (0.20–0.31)	0.893	22.15 (16.24–30.19)
<b>Cirrhosis</b>								
<b>MRE</b>	9 (1470)	4.63 (3.67–4.87)	89.5 (86.2–92.2)	92.0 (90.2–93.6)	10.74 (7.12–16.21)	0.10 (0.05–0.18)	0.972	132.66 (51.91–339.01)
<b>Fibroscan</b>	11 (2522)	12.17 (11–14)	80.0 (76.7–83.0)	86.6 (85.0–88.1)	5.81 (4.89–6.90)	0.25 (0.194–0.328)	0.905	23.24 (17.35–31.13)

<https://doi.org/10.1371/journal.pone.0186660.t002>

## Results of meta-analysis

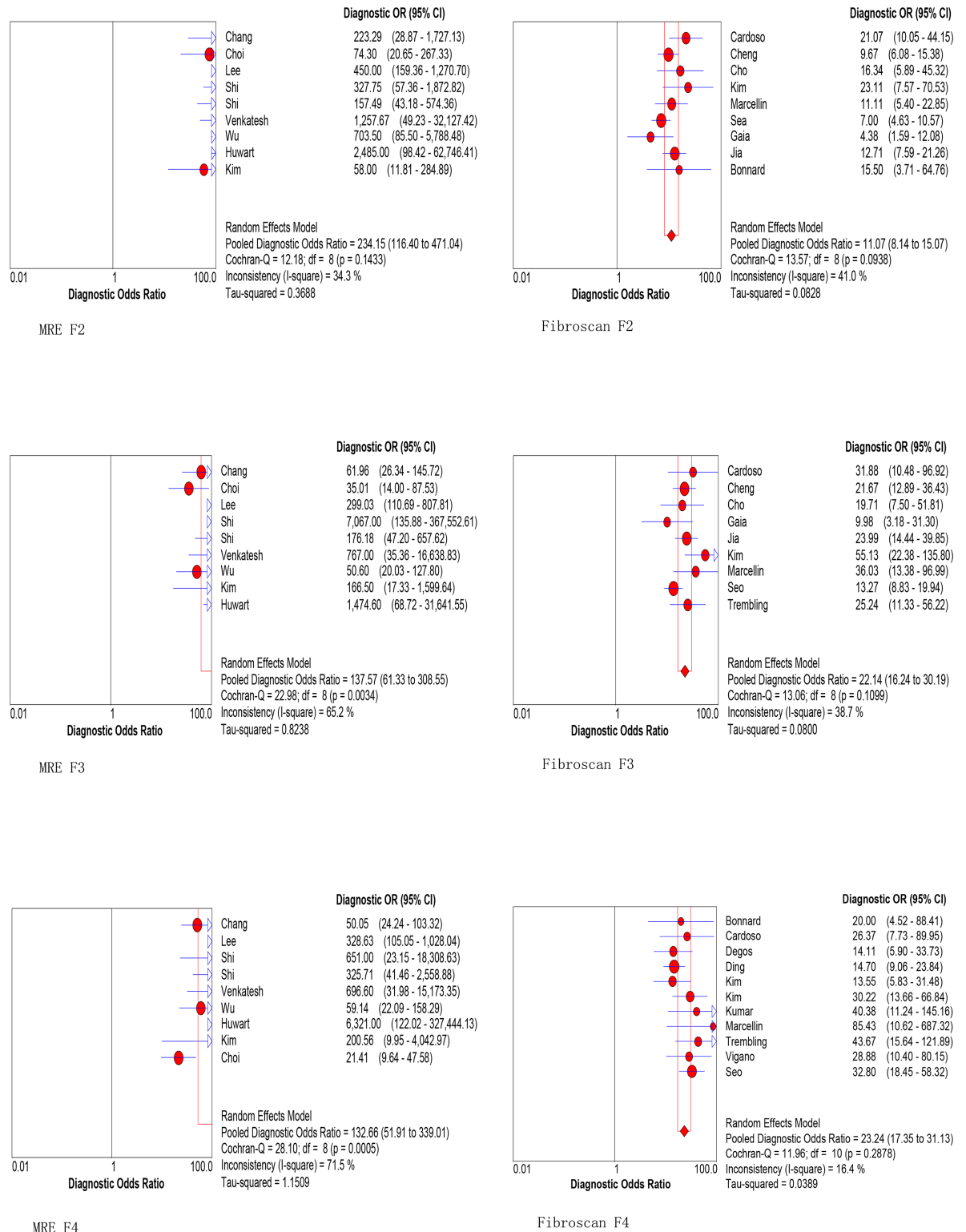
### Diagnostic accuracy of MRE and Fibroscan for the prediction of significant fibrosis.

Nine MRE studies including 1470 patients and Nine Fibroscan studies including 2314 patients were enrolled for diagnosis of significant fibrosis. As is shown in [Table 2](#), both the pooled sensitivity and specificity using MRE (92.8% and 93.7%) with a cutoff value of 2.99 kPa is higher than using Fibroscan for significant fibrosis (71.6% and 81.6%) with a cutoff value of 7.53 kPa. Furthermore, the summary DOR of MRE is superior to Fibroscan (234.15 vs 11.07, [Fig 3](#) MRE F2 vs. Fibroscan F2). More importantly, the summary AUROC values using MRE for detecting significant fibrosis was significantly higher than that using Fibroscan (0.981 vs. 0.794,  $P < 0.001$ , [Fig 4](#)).

### Diagnostic accuracy of MRE and Fibroscan for the prediction of advanced fibrosis.

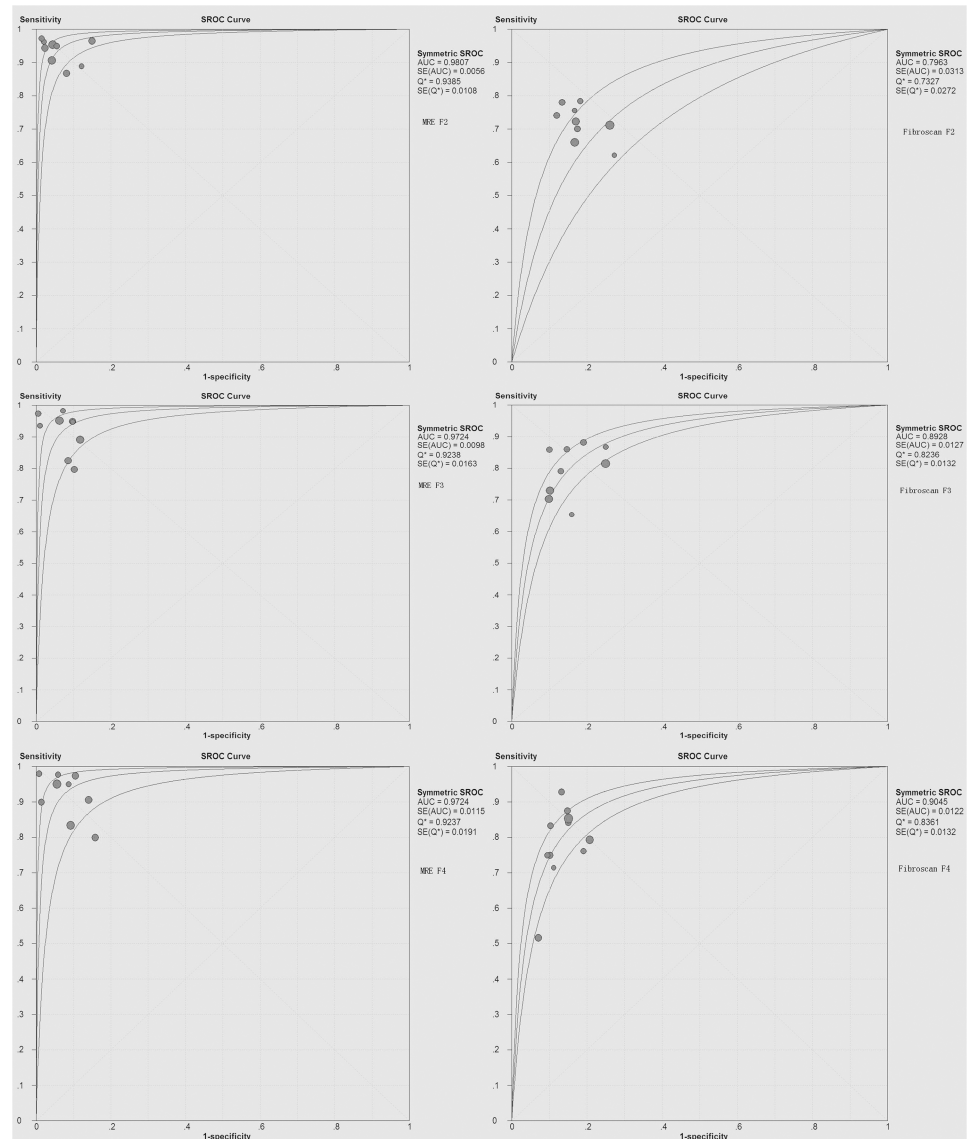
Nine MRE studies including 1470 patients and Nine Fibroscan studies including 2437 patients were enrolled for diagnosis of advanced fibrosis. As is shown in [Table 2](#), both the pooled sensitivity and specificity using MRE (89.6% and 93.2%) with a cutoff value of 3.62 kPa is higher than using Fibroscan for advanced fibrosis (79.0% and 84.6%) with a cutoff value of 9.15 kPa. Furthermore, the summary DOR of MRE is superior to Fibroscan (137.57 vs. 22.15, [Fig 3](#) MRE F3 vs. Fibroscan F3). More importantly, the summary AUROC value using MRE for detecting advanced fibrosis was significantly higher than that using Fibroscan (0.972 vs. 0.893,  $p < 0.001$ , [Fig 4](#)).

**Diagnostic accuracy of MRE and Fibroscan for the prediction of cirrhosis.** Nine MRE studies including 1470 patients and eleven Fibroscan studies including 2522 patients were enrolled for diagnosis of cirrhosis. As is shown in [Table 2](#), both the pooled sensitivity and specificity using MRE (89.5% and 92.0%) with a cutoff value of 4.63 kPa is higher than using Fibroscan for cirrhosis (80.0% and 86.6%) with a cutoff value of 12.17 kPa. Furthermore, the summary DOR of MRE is superior to Fibroscan (132.66 vs. 23.24, [Fig 3](#) MRE F4 vs. Fibroscan



**Fig 3. Forest plots of the DOR of MRE and Fibrosan for staging significant fibrosis (F2), advanced fibrosis (F3) and cirrhosis (F4).** The summary DOR of MRE is superior to Fibrosan for detecting significant fibrosis (F2), advanced fibrosis (F3) and cirrhosis (F4).

<https://doi.org/10.1371/journal.pone.0186660.g003>



**Fig 4. Summary ROC curve of the diagnostic accuracy of MRE and Fibrosan for staging significant fibrosis (F2), advanced fibrosis (F3) and cirrhosis (F4).** The summary AUROC values using MRE for detecting significant fibrosis(F2), advanced fibrosis(F3) and cirrhosis(F4) were all significantly higher than that using Fibrosan.

<https://doi.org/10.1371/journal.pone.0186660.g004>

F4). More importantly, the summary AUROC value using MRE for detecting cirrhosis was significantly higher than that using Fibrosan (0.972 vs. 0.905,  $p < 0.001$ , Fig 4).

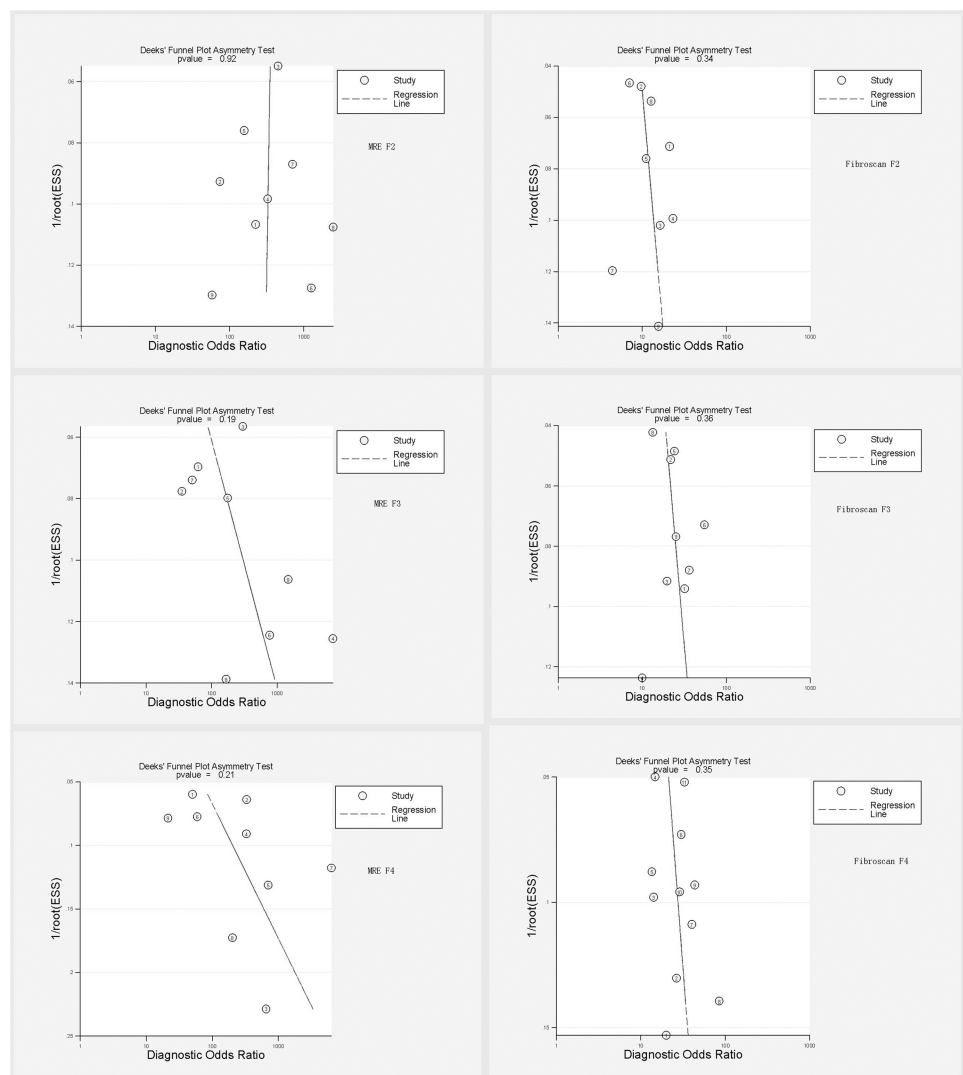
### Methodological heterogeneity and publication bias

Threshold heterogeneity was not observed in both MRE and Fibrosan studies. Non-threshold heterogeneity was observed in some groups, especially for MRE F3 and MRE F4 with substantial heterogeneities ( $I^2 = 65.2\%$  and  $71.5\%$ , respectively) (Table 3). Considerable heterogeneity and publication bias was not observed in both MRE and Fibrosan studies for detecting significant fibrosis, advanced fibrosis and cirrhosis in CHB patients (Fig 5).

**Table 3. Heterogeneity of all the included studies.**

Fibrosis stage	Threshold heterogeneity		Non-Threshold heterogeneity	
	r	p value	I <sup>2</sup> (%)	p
<b>MRE</b>				
F2	-0.383	0.308	34.3	0.143
F3	-0.600	0.088	65.2	0.003
F4	-0.550	0.125	71.5	<0.001
<b>Fibroscan</b>				
F2	-0.450	0.224	41.0	0.094
F3	0.500	0.170	38.7	0.110
F4	0.524	0.098	16.4	0.288

<https://doi.org/10.1371/journal.pone.0186660.t003>



**Fig 5. Deek's funnel plot asymmetry test for publication bias.** Considerable heterogeneity and publication bias was not observed in both MRE and Fibroscan studies for detecting liver fibrosis in CHB patients.

<https://doi.org/10.1371/journal.pone.0186660.g005>



## Discussion

Due to the controversial accuracy of MRE and Fibroscan for staging liver fibrosis, this current meta-analysis summarized the diagnosis accuracy of MRE and Fibroscan for detecting liver fibrosis in CHB patients. Finally, a total of nine MRE studies and fifteen Fibroscan studies were systematic reviewed. The results demonstrate that MRE had an excellent diagnostic accuracy for detecting liver fibrosis with a summary AUROC of 0.981, 0.972 and 0.972 for significant fibrosis, advanced fibrosis and cirrhosis, respectively, while Fibroscan had a moderate to excellent accuracy with a summary AUROC of 0.796, 0.893 and 0.905 respectively. MRE showed summary AUROC greater than 90% for detecting different stages of liver fibrosis in CHB patients. This is comparable to the results of the previous meta-analysis[35] (0.97, 0.96 and 0.97) which included patients with different etiologies. However, the summary AUROC values for Fibroscan detecting significant fibrosis was less than 80% in our meta-analysis, which was lower than the previous studies' results [36, 37]. In Chon's and Li's meta-analysis[5, 30], the mean AUROC for diagnosis significant fibrosis was 0.859 and 0.88. The sensitivity of Fibroscan for significant fibrosis in our review was also lower than that of Li's review (0.716 vs. 0.806). It might due to the reason that we reviewed the Fibroscan studies with similar liver stiff cutoff values recommended by WHO guidelines[6]. Therefore, the heterogeneity is lower than previous meta-analysis of Fibroscan for detecting liver fibrosis. Based on these results of our meta-analysis, we claim that both Fibroscan and MRE are excellent tools for diagnosis cirrhosis in CHB patients. However, MRE is more accurate than Fibroscan for detecting significant fibrosis and advanced fibrosis. Compared to shear wave elastography (SWE) reported in another meta-analysis[38], MRE showed greater summary AUROC for detecting significant fibrosis (0.98 vs 0.88). However, the diagnostic accuracy using SWE and MRE is comparable when detecting advanced fibrosis (sAUROC 0.972 vs 0.94) and cirrhosis (sAUROC 0.972 vs 0.92). Therefore, MRE might be used more popular as a noninvasive tool for detecting significant fibrosis in CHB patients.

The mean optimal cutoff values of MRE in our study were 2.99 for significant fibrosis, 3.62 for advanced fibrosis and 4.63 for cirrhosis. These cutoff values of MRE were lower than that of Singh's study[39] (3.66, 4.11 and 4.71) with 47.1% chronic hepatitis C patients. It may due to the different etiology in these two studies. Concerning to Fibroscan, the mean optimal cutoff values were 7.53, 9.15 and 12.17 for significant fibrosis, advanced fibrosis and cirrhosis, respectively. These were also lower than the studies in chronic hepatitis C (CHC) patients. For example, Stebbing et al[40] claimed higher cutoff values (8.44 kPa and 16.14 kPa for significant fibrosis and cirrhosis) when calculated only in CHC patients. This tendency of low cutoff values of Fibroscan in CHB patients and high cutoff values in CHC is similar to the results of Chon's study[5]. Sturm's[41] conclusion might explain this tendency. He claimed that the fibrous septa might be thinner in CHB patients than in CHC patients with the same liver fibrosis stage so that the total amount of liver fibrosis reflected by the fibrosis area was significantly lower in CHB patients.

There are some limitations in our study. Firstly, as MRE is a new elastography method, the number of MRE studies is so limited that we could not set more stringent inclusion criteria. For example, just enrolled prospective studies or enrolled only studies with clear information of the liver biopsy tissue length, or even enrolled studies with the similar distribution of the enrolled studies. Due to these reasons, non-threshold substantial heterogeneity was observed in MRE F3 and MRE F4 groups. Thus, large-scale, well-designed, and multi-center studies are needed to validate the conclusion and further evaluate the potential of MRE. Secondly, there are only a few studies focus on the direct comparison between MRE and Fibroscan. Hence, further large prospective direct comparison studies of MRE and Fibroscan should be



conducted to confirm the high accuracy of MRE in CHB patients. Finally, only SCI articles in English were selected for meta-analysis, this language and SCI restriction might bias the results to some extent.

## Conclusions

In summary, MRE is more accurate than Fibrosan in diagnosing liver fibrosis in CHB patients, especially in diagnosing significant fibrosis and advanced fibrosis. Although Fibrosan had a moderate accuracy in diagnosis significant fibrosis and advanced fibrosis, it is more cheaper and more easily popular used in clinical practice. Future studies on this issue should focus on standardization of the parameters for both imaging modalities to make them more feasible in clinical practice.

## Supporting information

**S1 PRISMA Checklist. PRISMA 2009 checklist.**  
(DOC)

## Author Contributions

**Conceptualization:** Huanming Xiao, Xiaoling Chi.

**Data curation:** Meijie Shi.

**Formal analysis:** Meijie Shi, Yubao Xie.

**Funding acquisition:** Xiaoling Chi.

**Investigation:** Yubao Xie.

**Methodology:** Huanming Xiao.

**Project administration:** Yubao Xie, Xiaoling Chi.

**Writing – original draft:** Huanming Xiao, Meijie Shi.

**Writing – review & editing:** Xiaoling Chi.

## References

1. Manning DS, Afdhal NH. Diagnosis and quantitation of fibrosis. *Gastroenterology*. 2008; 134(6):1670–81. <https://doi.org/10.1053/j.gastro.2008.03.001> PMID: 18471546
2. Lurie Y, Webb M, Cyter-Kuint R, Shteingart S, Lederkremer GZ. Non-invasive diagnosis of liver fibrosis and cirrhosis. *World Journal of Gastroenterology*. 2015; 21(41):11567–83. <https://doi.org/10.3748/wjg.v21.i41.11567> PMID: 26556987
3. Sebastiani G, Vario A, Guido M, Alberti A. Sequential algorithms combining non-invasive markers and biopsy for the assessment of liver fibrosis in chronic hepatitis B. *World Journal of Gastroenterology*. 2007; 13(4):525–31. <https://doi.org/10.3748/wjg.v13.i4.525> PMID: 17278217
4. Bonnard P, Sombie R, Lescure FX, Bougouma A, Guiard-Schmid JB, Poynard T, et al. Comparison of Elastography, Serum Marker Scores, and Histology for the Assessment of Liver Fibrosis in Hepatitis B Virus (HBV)-Infected Patients in Burkina Faso. *American Journal of Tropical Medicine and Hygiene*. 2010; 82(3):454–8. <https://doi.org/10.4269/ajtmh.2010.09-0088> PMID: 20207872
5. Chon YE, Choi EH, Song KJ, Park JY, Kim DY, Han KH, et al. Performance of Transient Elastography for the Staging of Liver Fibrosis in Patients with Chronic Hepatitis B: A Meta-Analysis. *Plos One*. 2012; 7(9).
6. Guidelines for the Prevention, Care and Treatment of Persons with Chronic Hepatitis B Infection. Geneva: World Health Organization 2015.; 2015 Mar.

7. Huwart L, Sempoux C, Vicaut E, Salameh N, Annet L, Danse E, et al. Magnetic resonance elastography for the noninvasive staging of liver fibrosis. *Gastroenterology*. 2008; 135(1):32–40. <https://doi.org/10.1053/j.gastro.2008.03.076> PMID: 18471441
8. Bohte Anneloes E dN A, Jansen Louis, Bipat Shandra, Nederveen Aart J., Verheij Joanne, Terpstra Valeska, Sinkus Ralph, van Nieuwkerk Karin M. J. dK RJ, Baak Bert C., Jansen Peter L. M., Reesink Henk W., Stoker Jaap. Non-invasive evaluation of liver fibrosis: a comparison of ultrasound-based transient elastography and MR elastography in patients with viral hepatitis B and C. *European radiology*. 2014;(24):638–48. <https://doi.org/10.1007/s00330-013-3046-0> PMID: 24158528
9. Whiting PF, Rutjes AWS, Westwood ME, Mallett S, Deeks JJ, Reitsma JB, et al. QUADAS-2: A Revised Tool for the Quality Assessment of Diagnostic Accuracy Studies. *Annals of Internal Medicine*. 2011; 155(8):529–U104. <https://doi.org/10.7326/0003-4819-155-8-2011110180-00009> PMID: 22007046
10. Bedossa P, Poynard T. An algorithm for the grading of activity in chronic hepatitis C. *Hepatology*. 1996; 24(2):289–93. <https://doi.org/10.1002/hep.510240201> PMID: 8690394
11. Batts KP, Ludwig J. Chronic Hepatitis—an Update on Terminology and Reporting. *American Journal of Surgical Pathology*. 1995; 19(12):1409–17. PMID: 7503362
12. Swets JA. Measuring the accuracy of diagnostic systems. *Science*. 1988; 240(4857):1285–93. PMID: 3287615
13. Cardoso AC, Carvalho RJ, Stern C, Dipumpo A, Giuily N, Ripault MP, et al. Direct comparison of diagnostic performance of transient elastography in patients with chronic hepatitis B and chronic hepatitis C. *Liver International*. 2012; 32(4):612–21. <https://doi.org/10.1111/j.1478-3231.2011.02660.x> PMID: 22103765
14. Chang W, Lee JM, Yoon JH, Han JK, Choi BI, Yoon JH, et al. Liver Fibrosis Staging with MR Elastography: Comparison of Diagnostic Performance between Patients with Chronic Hepatitis B and Those with Other Etiologic Causes. *Radiology*. 2016; 280(1):88–97. <https://doi.org/10.1148/radiol.2016150397> PMID: 26844364
15. Cheng JY, Hou JL, Ding HG, Chen GF, Xie Q, Wang YM, et al. Validation of Ten Noninvasive Diagnostic Models for Prediction of Liver Fibrosis in Patients with Chronic Hepatitis B. *Plos One*. 2015; 10(12).
16. Cho HJ, Seo YS, Lee KG, Hyun JJ, An HG, Keum B, et al. Serum aminotransferase levels instead of etiology affects the accuracy of transient elastography in chronic viral hepatitis patients. *Journal of Gastroenterology and Hepatology*. 2011; 26(3):492–500. <https://doi.org/10.1111/j.1440-1746.2010.06419.x> PMID: 21332545
17. Choi YR, Lee JM, Yoon JH, Han JK, Choi BI. Comparison of Magnetic Resonance Elastography and Gadoxetate Disodium-Enhanced Magnetic Resonance Imaging for the Evaluation of Hepatic Fibrosis. *Investigative Radiology*. 2013; 48(8):607–13. <https://doi.org/10.1097/RLI.0b013e318289ff8f> PMID: 23538889
18. Degos F, Perez P, Roche B, Mahmoudi A, Asselineau J, Voitot H, et al. Diagnostic accuracy of FibroScan and comparison to liver fibrosis biomarkers in chronic viral hepatitis: A multicenter prospective study (the FIBROSTIC study). *Journal of Hepatology*. 2010; 53(6):1013–21. <https://doi.org/10.1016/j.jhep.2010.05.035> PMID: 20850886
19. Ding DP, Li HB, Liu P, Chen LL, Kang J, Zhang YH, et al. FibroScan, aspartate aminotransferase and alanine aminotransferase ratio (AAR), aspartate aminotransferase to platelet ratio index (APRI), fibrosis index based on the 4 factor (FIB-4), and their combinations in the assessment of liver fibrosis in patients with hepatitis B. *International Journal of Clinical and Experimental Medicine*. 2015; 8(11):20876–82. PMID: 26885013
20. Gaia S, Carenzi S, Barilli AL, Bugianesi E, Smedile A, Brunello F, et al. Reliability of transient elastography for the detection of fibrosis in Non-Alcoholic Fatty Liver Disease and chronic viral hepatitis. *Journal of Hepatology*. 2011; 54(1):64–71. <https://doi.org/10.1016/j.jhep.2010.06.022> PMID: 20932598
21. Jia JD, Hou JL, Ding HG, Chen GF, Xie Q, Wang YM, et al. Transient elastography compared to serum markers to predict liver fibrosis in a cohort of Chinese patients with chronic hepatitis B. *Journal of Gastroenterology and Hepatology*. 2015; 30(4):756–62. <https://doi.org/10.1111/jgh.12840> PMID: 25353058
22. Kim BH, Lee JM, Lee YJ, Lee KB, Suh KS, Han JK, et al. MR Elastography for Noninvasive Assessment of Hepatic Fibrosis: Experience From a Tertiary Center in Asia. *Journal of Magnetic Resonance Imaging*. 2011; 34(5):1110–6. <https://doi.org/10.1002/jmri.22723> PMID: 21932355
23. Kim BK, Kim HS, Park JY, Kim DY, Ahn SH, Chon CY, et al. Prospective Validation of ELF Test in Comparison with Fibroscan and FibroTest to Predict Liver Fibrosis in Asian Subjects with Chronic Hepatitis B. *Plos One*. 2012; 7(7).
24. Kim SU, Ahn SH, Park JY, Kang W, Kim DY, Park YN, et al. Liver Stiffness Measurement in Combination With Noninvasive Markers for the Improved Diagnosis of B-viral Liver Cirrhosis. *Journal of Clinical*

- Gastroenterology. 2009; 43(3):267–71. <https://doi.org/10.1097/MCG.0b013e31816f212e> PMID: 18987556
25. Kumar M, Rastogi A, Singh T, Bihari C, Gupta E, Sharma P, et al. Analysis of discordance between transient elastography and liver biopsy for assessing liver fibrosis in chronic hepatitis B virus infection. *Hepatology International*. 2013; 7(1):134–43. <https://doi.org/10.1007/s12072-012-9380-5> PMID: 26201627
  26. Lee JE, Lee JM, Lee KB, Yoon JH, Shin CI, Han JK, et al. Noninvasive Assessment of Hepatic Fibrosis in Patients with Chronic Hepatitis B Viral Infection Using Magnetic Resonance elastography. *Korean Journal of Radiology*. 2014; 15(2):210–7. <https://doi.org/10.3348/kjr.2014.15.2.210> PMID: 24643284
  27. Marcellin P, Ziol M, Bedossa P, Douvin C, Poupon R, de Ledinghen V, et al. Non-invasive assessment of liver fibrosis by stiffness measurement in patients with chronic hepatitis B. *Liver International*. 2009; 29(2):242–7. <https://doi.org/10.1111/j.1478-3231.2008.01802.x> PMID: 18637064
  28. Seo YS, Kim MY, Kim SU, Hyun BS, Jang JY, Lee JW, et al. Accuracy of transient elastography in assessing liver fibrosis in chronic viral hepatitis: A multicentre, retrospective study. *Liver International*. 2015; 35(10):2246–55. <https://doi.org/10.1111/liv.12808> PMID: 25682719
  29. Shi Y, Guo QY, Xia F, Dzyubak B, Glaser KJ, Li QJ, et al. MR Elastography for the Assessment of Hepatic Fibrosis in Patients with Chronic Hepatitis B Infection: Does Histologic Necroinflammation Influence the Measurement of Hepatic Stiffness? *Radiology*. 2014; 273(1):88–98. <https://doi.org/10.1148/radiol.14132592> PMID: 24893048
  30. Shi Y, Xia F, Li QJ, Li JH, Yu B, Li Y, et al. Magnetic Resonance Elastography for the Evaluation of Liver Fibrosis in Chronic Hepatitis B and C by Using Both Gradient-Recalled Echo and Spin-Echo Echo Planar Imaging: A Prospective Study. *American Journal of Gastroenterology*. 2016; 111(6):823–33. <https://doi.org/10.1038/ajg.2016.56> PMID: 26977760
  31. Trembling PM, Lampertico P, Parkes J, Tanwar S, Vigano M, Facchetti F, et al. Performance of Enhanced Liver Fibrosis test and comparison with transient elastography in the identification of liver fibrosis in patients with chronic hepatitis B infection. *Journal of Viral Hepatitis*. 2014; 21(6):430–8. <https://doi.org/10.1111/jvh.12161> PMID: 24750297
  32. Venkatesh SK, Wang G, Lim SG, Wee A. Magnetic resonance elastography for the detection and staging of liver fibrosis in chronic hepatitis B. *European Radiology*. 2014; 24(1):70–8. <https://doi.org/10.1007/s00330-013-2978-8> PMID: 23928932
  33. Vigano M, Paggi S, Lampertico P, Fraquelli M, Massironi S, Ronchi G, et al. Dual cut-off transient elastography to assess liver fibrosis in chronic hepatitis B: a cohort study with internal validation. *Alimentary Pharmacology & Therapeutics*. 2011; 34(3):353–62.
  34. Wu WP, Chou CT, Chen RC, Lee CW, Lee KW, Wu HK. Non-Invasive Evaluation of Hepatic Fibrosis: The Diagnostic Performance of Magnetic Resonance Elastography in Patients with Viral Hepatitis B or C. *Plos One*. 2015; 10(10).
  35. Guo Y, Parthasarathy S, Goyal P, McCarthy RJ, Larson AC, Miller FH. Magnetic resonance elastography and acoustic radiation force impulse for staging hepatic fibrosis: a meta-analysis. *Abdominal Imaging*. 2015; 40(4):818–34. <https://doi.org/10.1007/s00261-014-0137-6> PMID: 24711064
  36. Foucher J, Chanteloup E, Vergniol J, Castera L, Le Bail B, Adhoute X, et al. Diagnosis of cirrhosis by transient elastography (FibroScan): a prospective study. *Gut*. 2006; 55(3):403–8. Epub 2005/07/16. <https://doi.org/10.1136/gut.2005.069153> PMID: 16020491
  37. Wong GL, Wong VW, Choi PC, Chan AW, Chan HL. Development of a non-invasive algorithm with transient elastography (Fibroscan) and serum test formula for advanced liver fibrosis in chronic hepatitis B. *Alimentary pharmacology & therapeutics*. 2010; 31(10):1095–103. Epub 2010/02/26. <https://doi.org/10.1111/j.1365-2036.2010.04276.x> PMID: 20180785
  38. Li CT, Zhang CS, Li JL, Huo HP, Song DF. Diagnostic Accuracy of Real-Time Shear Wave Elastography for Staging of Liver Fibrosis: A Meta-Analysis. *Medical Science Monitor*. 2016; 22:1349–59. <https://doi.org/10.12659/MSM.895662> PMID: 27102449
  39. Singh S, Venkatesh SK, Wang Z, Miller FH, Motosugi U, Low RN, et al. Diagnostic Performance of Magnetic Resonance Elastography in Staging Liver Fibrosis: A Systematic Review and Meta-analysis of Individual Participant Data. *Clinical Gastroenterology and Hepatology*. 2015; 13(3):440–51. <https://doi.org/10.1016/j.cgh.2014.09.046> PMID: 25305349
  40. Stebbing J, Farouk L, Panos G, Anderson M, Jiao LR, Mandalia S, et al. A Meta-analysis of Transient Elastography for the Detection of Hepatic Fibrosis. *Journal of Clinical Gastroenterology*. 2010; 44(3):214–9. <https://doi.org/10.1097/MCG.0b013e3181b4af1f> PMID: 19745758
  41. Sturm N, Cheveau A, Arvers P, Leroy V, Zarski JP. Comparative Morphometric Assessment of Fibrosis in Chronic Hepatitis B (Chb) Versus Chronic Hepatitis C (Chc) Liver Biopsies: Implication for Fibrosis Assessment by Non Invasive Methods. *Journal of Hepatology*. 2009; 50:S144–S.